

Chapter 25

Hand Fractures and Dislocations

Bill Rhodes and Louis Carter

Preface

This chapter is included for those surgeons who have the time, knowledge, expertise and equipment to handle hand fractures. Many general surgeons in remote hospitals may not have the time to treat hand fractures, even though it is important to the individual patient to have a functional hand. If the surgeon is comfortable in treating fractures, then this chapter will enable one to treat fractures of the hand in district hospitals in the Sub-Saharan area. Most closed hand fractures will be splinted or casted with or without attempted manipulation. With most closed fractures closed treatment is best and allows for good and rapid healing. This chapter is written to give guidelines for those closed fractures that are grossly displaced, angulated or rotated and for the treatment of open fractures. Common dislocations will also be covered. Attempt will be made to give the surgeon a simple method for treating these injuries with the equipment and technology that is available in district hospitals. Hand anatomy and hand incisions are shown in basic texts that most hospitals will have available. These should be available your operating room before you begin surgery.

Introduction

Traumatic injuries to the hand present a significant challenge to the general surgeon because of the complex anatomy and the endless number of possible traumatic scenarios. Injuries can range from simple closed fractures to complex open wounds that involve both fractures and injuries to tendon and neurovascular structures. The goal of this chapter will be to describe the common fractures/dislocations and treatment options within a clinical context that has limited diagnostic and treatment capabilities (e.g., C-arms with fluoroscopy and small plates and screws).

There are several factors that are especially relevant when considering fractures/dislocations of the hand in the developing world context:

- 1) Delay in seeking medical attention
- 2) Delay in treatment because of other life or limb threatening injuries
- 3) Forced dependency on physical exam with the lack of specialized diagnostic capabilities
- 4) The lack of available internal and external fixation devices for stabilization of hand fractures/dislocations (Indian suppliers of these can be found across Africa now).

- 5) Non-compliance in postoperative follow-up for wound care and physical therapy
- 6) The general lack of trained therapists for rehabilitation after hand injuries

Even the best surgical intervention can be undermined by the non-compliance of the patient during the postoperative phase as well the inability to provide timely and effective hand therapy to restore function. The surgeon must take a realistic approach in the management of hand fractures to deliver the best result possible. While there are few actual hand therapists in the Sub-Saharan Africa, there are many physical and occupational therapists. Unfortunately, few of these have actual hands on experience in hand therapy and very few of these are in district hospitals.) Thus, the doctor must also be his therapist in these hospitals.

Because of the lack of fluoroscopy (C-arms) many fractures/dislocations that potentially could be treated by closed methods must be treated by open reduction for direct visualization and simple percutaneous pinning with Kirschner wires. Actually even with a C-arm, percutaneous pinning with K-wires can be a very difficult procedure which often requires a lengthy learning curve.

(Editor's Note: Open reduction and internal fixation should only be carried out for the most severe of closed hand fractures. Open reduction is not without complications and scarring after open reduction will often leave the patient's hand stiffer than it would have ever been—maybe reduced but non-functional. A painful non-union in a hand that moves is better and easier treated than a painless union in a stiff hand. If the wound is already open, then one should go ahead and fix significantly displaced or angulated fractures and dislocations.)

Initial Evaluation

All fractures and dislocations involving the metacarpals and phalanges should be assessed in a thorough and thoughtful manner. An appropriate history and physical exam must be performed. Concerns include:

- ◆ The time since the injury occurred, hours, days, weeks, or even months
- ◆ Specific site of pain, tenderness, swelling, deformity, and if there is an open wound

- ◆ Determine if inability of movement is secondary to pain, fracture, tendon or nerve injury
- ◆ Determine if there are other associated upper extremity injuries involving elbow or shoulder
- ◆ Review appropriate x-rays to evaluate any fracture/dislocation.
 - The basic hand views are AP, lateral and oblique. Often oblique x-rays are not taken but some oblique, spiral and small intra-articular fractures may be missed unless oblique views are also taken.
 - X-ray technicians must learn to take films of an individual finger alone and not the entire hand when only a single finger is injured. A full hand x-ray often does not show a finger deformity clearly.
 - There are special x-rays to help diagnose certain fractures when clinical exam suggests a fracture and routine x-rays fail to demonstrate an abnormality. These will be mentioned below.

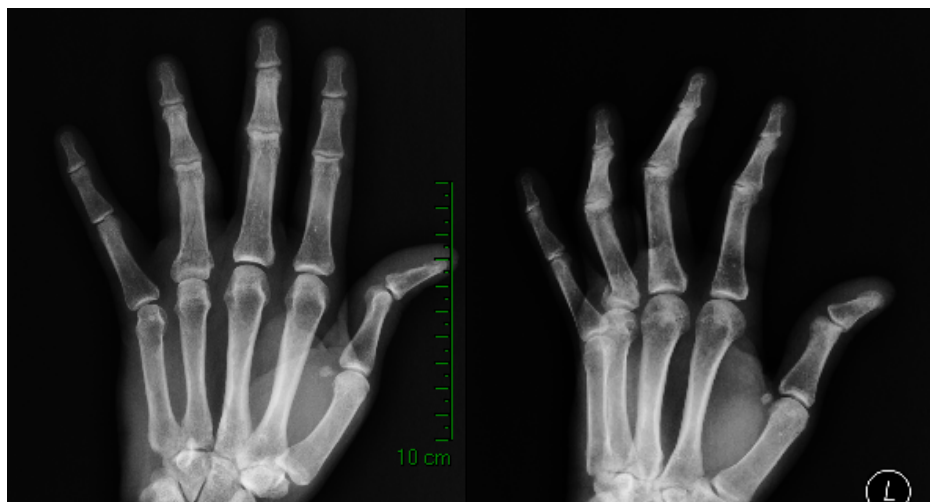


Fig 1

Fig 2

Importance of oblique views—see base of ring proximal phalanx
Fracture difficult to see on PA view but obvious on oblique

Initial Care

Prompt attention to cleaning all wounds or open fracture sites is a priority. This may require sedation with local or regional anesthesia or even general anesthesia. Hand and upper extremity wounds can be débrided and closed if < 24 hours old. Ideally tendon, nerve and bony injuries will be treated acutely. If someone with the expertise to repair these structures is not available, then débridement and copious irrigation should be followed by loose closure (see chapter on Wound Closure—“Clean Closed Wound Concept.”) The hand should be elevated at all times postop. Definitive repair can be performed later as this is now a clean closed wound. DO NOT just dress an open wound with the thought of definitive surgery the following day. It is always best to loosely close the wound immediately if adequate débridement

has been carried out since no one can predict the operating room schedule the next day. Ideally delayed repair should be done as soon as possible but a delay of 7-10 days is not harmful. Systemic antibiotics should be given in cases of open fractures and where there has been contamination.

With injuries presenting after 24 hours, repeated débridements may be necessary for several days before the wound can be safely closed. Sometimes the use of a VAC will be necessary. Since soft tissues of the hand are well vascularized, minimal débridement is usually sufficient along with removal of all obviously necrotic tissue and foreign bodies. In the rare case that a wound cannot be closed, it is important to keep the wound moist and the extremity elevated between débridements.

Basic Nomenclature of fractures and dislocations

- ◆ Angulation: The position of the apex of the fracture determines whether the angulation is dorsal or volar. Metacarpal fractures often have an apex dorsal angulation whereas proximal phalanx fractures have an apex volar angulation due to muscle forces.
- ◆ Rotation: Common in oblique and spiral fractures and can be diagnosed by actively or passively flexing the fingers into the palm. Overlap of the fingers is seen. Rotation can also be identified by comparing the plane of adjacent fingernails. Rotation must be corrected as 5° of rotation at the metacarpal level can result in 1.5 cm of overlap of the fingers.
- ◆ Dislocation: The position of the distal bone determines whether the dislocation is dorsal or volar.
- ◆ Displacement: When the bone fragments on each side of the fracture are not in alignment with each other.
- ◆ Comminuted: When there are multiple fracture fragments.

Anesthesia

The choice of anesthesia depends on what is available in your hospital. For adults, an axillary block or Bier block is fine for all hand injuries. A wrist or digital block will be satisfactory for finger injuries. Ketamine is also sufficient for closed reductions and especially for children. A tourniquet should be used with any open fracture or open procedure. General anesthesia may sometimes be required.

Once x-rays have been taken and the diagnosis confirmed, a **hematoma block** with lidocaine in the casualty department or operating room will give good anesthesia for an early reduction and casting/splinting of some fractures.

When closed pinning is suggested below, this can be done either in the OR (theatre) with a portable x-ray or even better in the x-ray department if safe anesthesia and sterile conditions can be maintained.

Resources

Keep an anatomy book in your OR at all times and refer to it on the cases below.

Metacarpal Base (CMCJ) Fractures and dislocations

Thumb

Special x-ray view of Thumb CMCJ: Robert's view—forearm pronated, shoulder internally rotated and thumb abducted against the film.

- ◆ **CMCJ dislocation** of the thumb without a fracture on AP, lateral and oblique views of the thumb: An isolated CMCJ dislocation is usually dorsal. If closed reduction is successful, a spica plaster should be applied for 6 weeks, before range of motion is initiated. If closed reduction is unsuccessful, then an incision can be made along the radial border of the thumb with a palmar extension along the distal wrist crease (Wagner) and open reduction and pinning with K-wires carried out. One must preserve the dorsal branches of the radial nerve in this incision. The thenar muscles are reflected volarly off the metacarpal in order to better visualize the joint.
- ◆ **Bennett's fracture** is an oblique intraarticular fracture of the metacarpal base with the undisplaced ulnar fragment attached to the anterior oblique ligament or metacarpotrapezial ligament. The large radial shaft fragment is displaced dorsally, proximally and radially with the pull of the abductor pollicis longus tendon. Though this is an unstable fracture pattern, closed reduction may be attempted by traction on the thumb with abduction and pressure over the radial side of the thumb base while applying a thumb spica cast which includes the wrist joint and the thumb MP joint. If it is difficult to hold reduction, one or two K-wires may be passed from the thumb metacarpal base blindly into the carpus before the spica cast is applied.

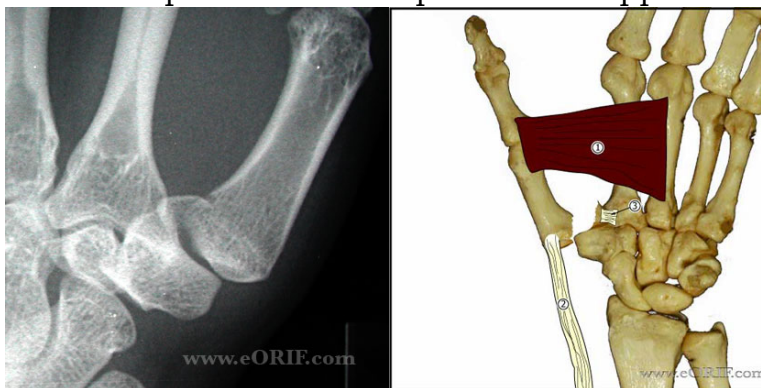


Fig 3

Fig 4

Bennett's Fracture showing pull of adductor ulnarly and APL proximally
(Courtesy of eORIF.com)

- ◆ If followup x-rays show reduction, the patient should be followed weekly to ensure reduction is maintained.

If the fracture cannot be reduced or reduction maintained, an incision as described above is used. The fracture site is exposed, the metacarpal reduced and two .045 in. Kirschner wires are inserted from the radial thumb metacarpal shaft into the ulnar fragment or proximal trapezium and carpal bones. If the ulnar fracture fragment is large enough, direct pinning into it with two K-wires can be done. A thumb spica radial gutter splint is applied. The pins are removed at 3 weeks and the splint is continued for a full six weeks. Range of motion is then begun.

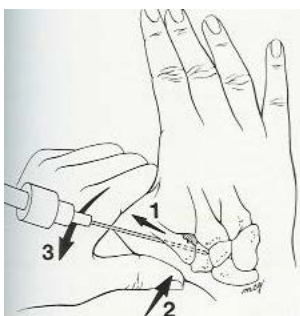


Fig 5 Method to reduce Bennett's fracture: traction, abduction, pressure at base
(Courtesy of eORIF.com)

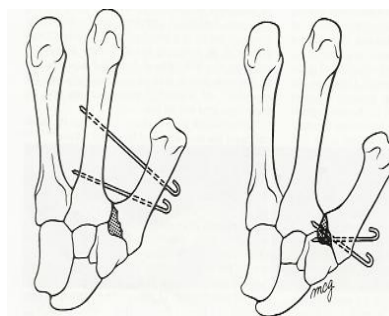


Fig 6 Other methods of fixation
(Courtesy of eORIF.com)

- ◆ **Rolando fracture** is a rare comminuted intraarticular, V-shaped fracture of the metacarpal base. Closed reduction with or without pinning is rarely successful. Open reduction and pinning is difficult but can be attempted if there are large displaced fragments. External fixation with traction on a distal pin may be best—pins through the trapezium or carpus and a distal pin through the distal metacarpal or proximal phalanx. Skeletal traction can be performed by placing these K-wires and incorporating the wires in a thumb spica cast while applying traction. If these techniques are not possible, simply placing the thumb in a spica splint or cast for 3 weeks and then beginning range of motion exercises early may be best that can be done.

(Editor's Note: It cannot be over emphasized that closed reduction with splinting or casting is best if one does not have experience with this surgery and is not certain of hand anatomy. Immobilization for 3 weeks followed by early exercises will often result in a functional hand.)

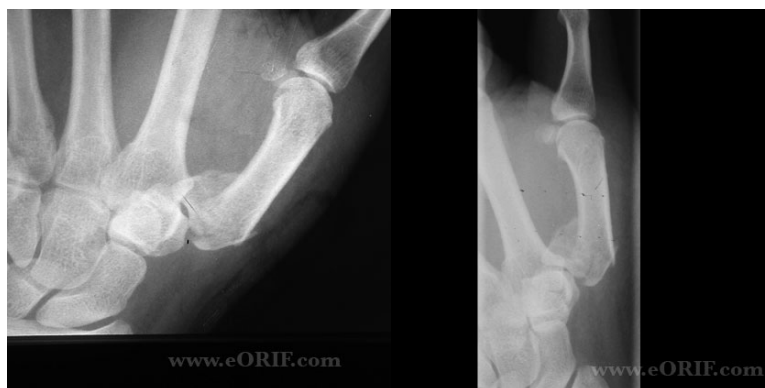

Fig 7
Fig 8
Rolando Fracture PA and Lateral views
(Courtesy of eORIF.com)

- ◆ Open fractures of the thumb CMCJ will be treated the same way after adequate cleansing and débridement.

Metacarpal Dislocations of other digits

- ◆ The most common CMC joint fracture/dislocation involves either the ring or small finger or both. The **best x-ray** to ascertain these fracture dislocations is with the hand held in 30 degrees pronated from a fully supinated position. The fracture dislocation of the small finger is similar to the Bennett's fracture of the thumb. The distal fragment is dislocated dorsally and proximally by the pull of the extensor carpi ulnaris tendon. Stabilization of these fractures may be difficult to maintain with simply closed reduction and splinting/casting. Two K-wires can be passed blindly after reduction into the carpus and/or ring finger. If this is not possible it is acceptable to treat these with splinting and early range of motion rather than an open reduction and pinning.

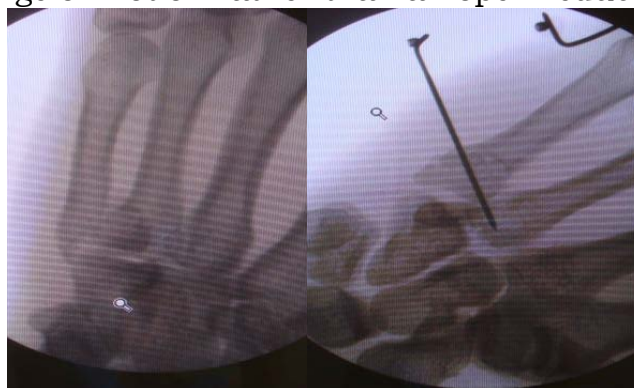

Fig 9 Fracture dislocation small CMC joint
(Courtesy Dr. Jason Rehm)

- ◆ **CMC fracture dislocation** involving the index, long, ring or small finger can be suspected by significant swelling over the dorsum of the hand.

These are due to high energy injuries. These are usually dorsal and often there may be fracture fragments present. The **best x-ray** to ascertain these fracture dislocations is with the hand held in 30 degrees pronated from a fully supinated position. With these fracture dislocations it is difficult to maintain stabilization with closed reduction. Blind retrograde pinning from the metacarpal into the carpus is possible once swelling has subsided. The sure option is by open reduction through a dorsal incision with direct visualization and insertion of K-wires in a retrograde manner. If these dislocations are open, reduction and pinning as above will be more easily performed.

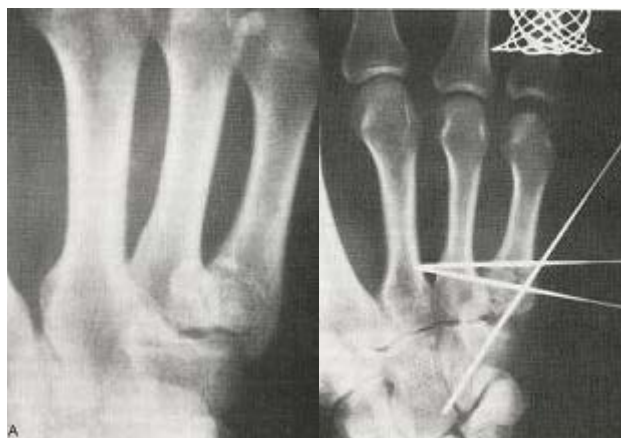

Fig 10

Fig 11

Fracture dislocation base small finger If severely displaced, treat with pins as above but casting will work fine in most cases if one lacks experience and x-ray control

- ◆ Volar dislocations result from significant force and are rare and frequently missed. Open reduction is indicated after swelling has subsided. In any CMCJ dislocation, associated fractures may cause rotation and before and after pinning, great care should be taken to rule out rotation by flexing the fingers into the palm.

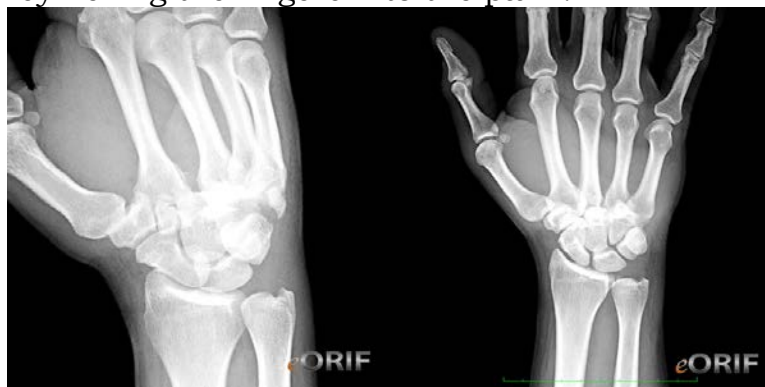

Fig 12

Fig 13

Carpometacarpal fracture dislocations are rare and usually dorsal. Both dorsal and volar are due to high energy forces and are often associated with other severe injuries. There is significant soft tissue swelling and surgery should be delayed until swelling subsides with elevation. (Courtesy of eORIF.com)

(Editor's Note: These are severe injuries with significant swelling. Reduction and pinning is not easy and without experience these may be splinted and early motion begun.)

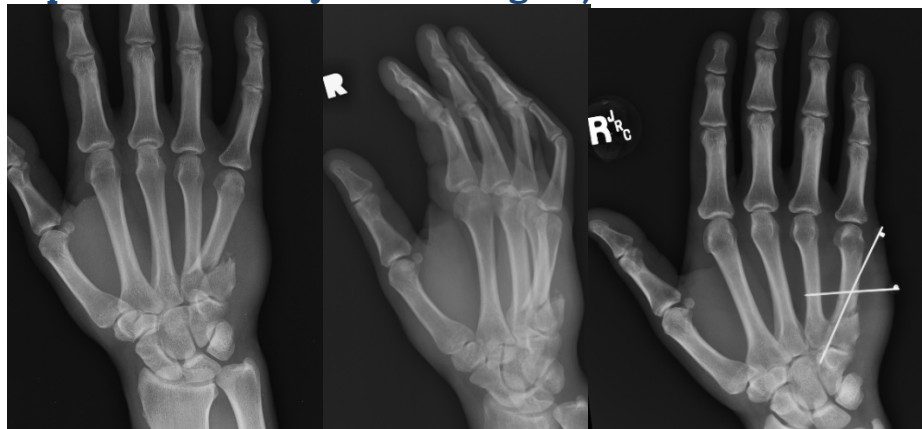

Fig 14

Fig 15

Fig 16

Non-intraarticular fracture of metacarpal base: Treat closed unless open fracture. If significant angulation, above pinning is an excellent method of stabilization. One will need x-ray control for pinning.

Metacarpal Fractures:

- ◆ Metacarpal fractures may be at the base, in the shaft or at the neck. They can occur in transverse, spiral, or oblique fracture patterns. Shortening at an isolated fracture site of up to one centimeter may be acceptable if there is no rotational deformity. Angulation may be accepted if the angulation is less than 10° in index and long, less than 20° in ring and less than 25° in small. Rotational deformity of even a few degrees is unacceptable. If closed reduction is performed, great care must be taken to ensure stability without rotational deformity. Many shaft fractures can be managed by close reduction and casting for 4 weeks with the wrist extended 20-30° and MP joints flexed. The cast is extended out to the PIP joints but these are left free to move. Fingers can be buddy-taped together to help correct and prevent rotation. Transverse fractures are often angulated with the apex dorsal. Reduction is accomplished by traction, flexion of MP joints and dorsal pressure over the metacarpal shaft while applying the cast. (Jahss Maneuver)
- ◆ A single metacarpal fracture should be treated with closed reduction and casting. **Rarely will it be necessary to open a single metacarpal fracture.** If closed reduction is possible but maintenance of stabilization is not possible in a border metacarpal, percutaneous closed pinning may be attempted but it is difficult without a C-arm. This can

be accomplished by maintaining reduction and placing several K-wires transversely across the metacarpals pinning the fractured metacarpals to normal ones above and below the fracture site.

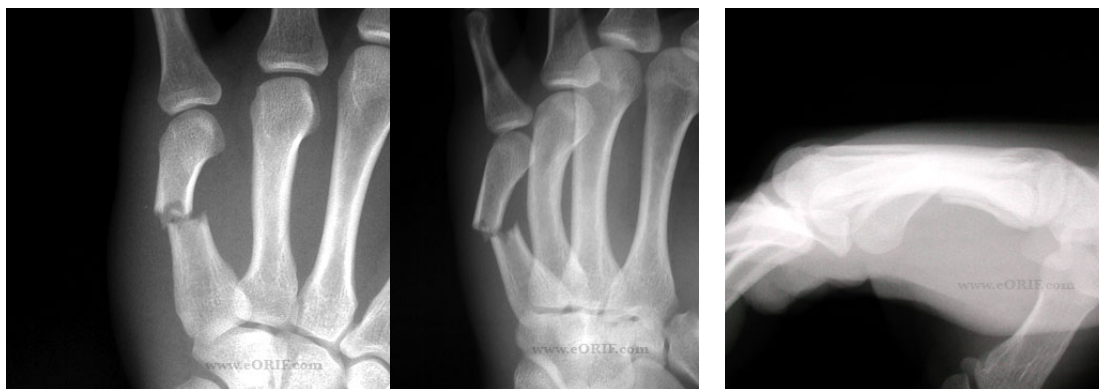

Fig 17
Metacarpal shaft fracture with 60 degrees apex dorsal angulation
Fig 18
Fig 19
(Courtesy of eORIF.com)

◆ **Open reduction may be needed in the following situations:**

- there are multiple fractures
- the fracture(s) is significantly displaced and bony approximation cannot be corrected by closed reduction,
- rotation cannot be corrected
- open displaced or rotated fractures.
- Spiral, oblique central metacarpal (long and ring) fractures require closed correction of rotation. Shortening will not be significant and does not require open reduction.

For all hand fractures, if a C-arm is NOT available, a portable x-ray in the theatre can be used. If a portable x-ray is unavailable, then the patient can be given a regional block and taken to x-ray where serial x-rays can be taken after each attempt at reduction. The patient should be closely monitored by anesthesia personnel. If pinning is performed in the x-ray department, great care must be taken to maintain a sterile environment.

◆ **Methods of ORIF-open reduction and internal fixation**

1. Transverse K-wires above and below fracture into normal metacarpals (percutaneous and closed if possible—recommended)
2. Crossed K-wires, bent, inserted antegrade from base of metacarpal (this may be difficult without experience)
3. Crossed K-wires passed retrograde through MC head (usually requires x-ray control and experience)

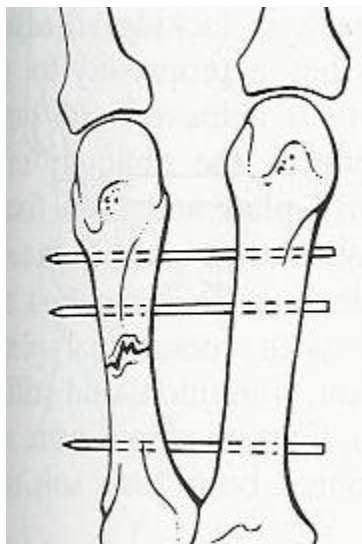


Fig 20

K-wires above and below the fracture and into adjacent normal metacarpal
(Courtesy of eORIF.com)

4. Crossed K-wires passed antegrade from the fracture site through the distal fragment until they emerge through the distal cortex and then passed retrograde into the proximal fragment—when open reduction.

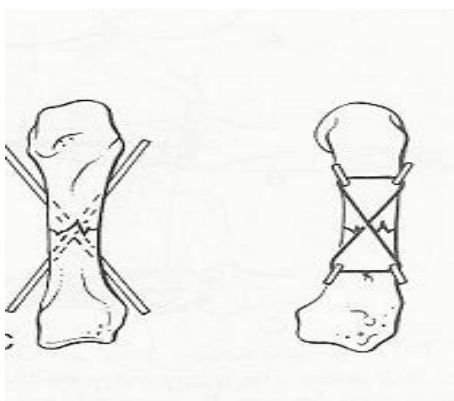


Fig 21

Crossed K-wires—ORIF only if fracture open
(Courtesy of eORIF.com)

5. One K-wire through the fracture and one or two interosseous 24 gauge steel wire for oblique border metacarpals

6. One K-wire through the fracture and cerclage steel wires—if the fracture is oblique or spiral

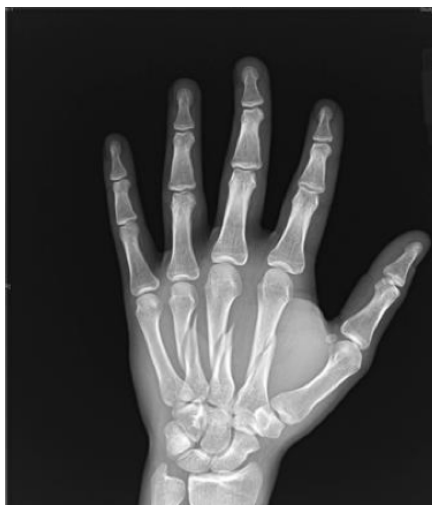

Fig 22

Spiral metacarpal fractures: Index fracture appears stable in this view.

There is likely minimal shortening of ring and long. If closed but angulated these fractures would be best treated with K-wires from small to ring and long under x-ray control. If this is not possible or if angulation is minimal, closed treatment with casting in position of protection is best—MPJs flexed and IPJs extended. If these fractures are open, then they may be treated with interosseous wires, cerclage wires or small interfragmentary compression screws if available

7. 90:90 stainless steel 24 gauge wire sutures—excellent stabilization, if one must open a fracture or if the fracture is open. Use 0.045 K-wires to make **horizontal and vertical** drill holes through both ends 5 mm from fracture. (K-wire is passed from 3 to 9 and 12 to 6 at each end.) A 19 gauge needle is passed through the drill holes and a wire suture or stainless steel wire is inserted through the needle. The wire is pulled through, needle removed, and then the wire is passed back through another needle in the opposite fragment drill hole. The sutures can then be twisted down. This method is ideal for an unstable transverse fracture.

- If there is rotation of a transverse fracture, the first or last two techniques will likely be necessary.
- Towel clips are excellent to temporarily stabilize the spiral or oblique fracture
- Open, rotated spiral fractures may be treated with K-wires into adjacent stable metacarpals or K-wires or interosseous wires across the fragments

Pinning methods above should be carried out with .028, .035 or .045 K-wires according to the size of the metacarpal. If possible K-wires should be left just outside the skin so they can be removed at 3 weeks. If not, they can be left beneath the skin without difficulty

Casting these fractures in the “protective position” is necessary as none of the above techniques will give rigid fixation except the 90:90 wiring.

Exposure for metacarpal fracture fixation is through the laceration or through longitudinal incision along one side of an extensor tendon. Adjacent metacarpals can be approached by an incision midway between them.

Protective position: Wrist slight extended, MPJ flexed 80-90° and IPJ extended

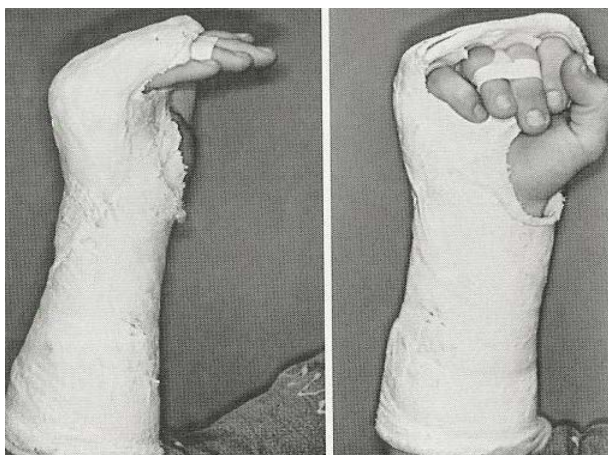


Fig 22

Fig 23

Casted in protective position. Note buddy-taping between ring and long to help prevent rotation (Courtesy of eORIF.com)

Protective position: Wrist slight extended, MPJ flexed 80-90° and IPJ extended

Editor’s Note: Many will not have expertise in this surgery and many metacarpal fractures will be treated closed with casting. Just be certain that rotation has been corrected and motion is started after 3—4 weeks. A volar splint or gutter splint is worn when not exercising during the next 3 weeks. Rotation can be determined by flexing the fingers into a fist to ensure there is no overlap and by ensuring the fingernails are parallel. All the fingers tips should point to the scaphoid—see below.

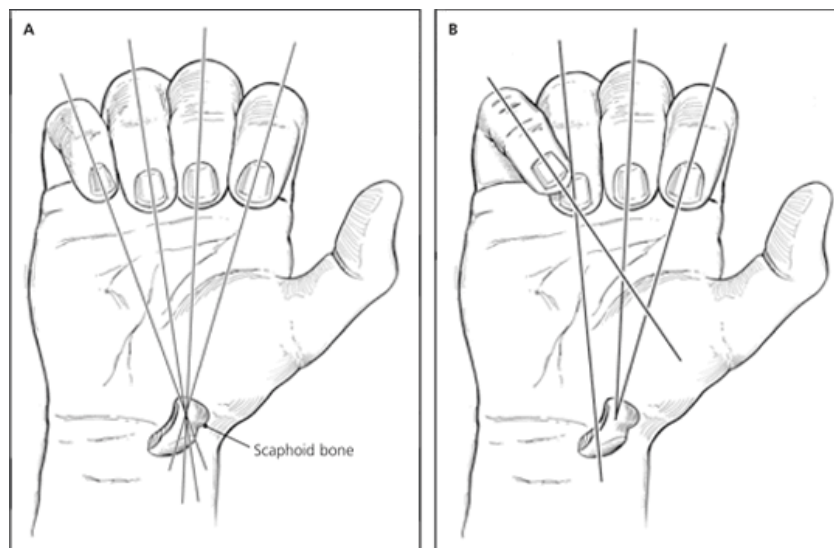


Fig. 24

Fig 25

Finger tips should point to scaphoid. Note overlapping between the small and ring finger tips on the right.

- ◆ **Comminuted fractures** or those with segmental loss are best treated with transmetacarpal K-wires above and below the comminution and into normal metacarpals as described above or using a mini-external fixator if only one metacarpal involved. Home-made external fixators can be constructed using two K-wires above and below the fracture and held together with plaster or methylmethacrylate—an endotracheal tube filled with methylmethacrylate is a good “external fixator.” As the methylmethacrylate is hardening, the K-wires are stuck through the tube as the fracture is distracted and aligned. If segmental loss, bone grafting can be carried out as a second stage. If open with segmental loss, a K-wire can also be used as an intramedullary pin to hold the metacarpal out to length. Two right angle turns are made at each end and placed in both fractured ends of the bone. Severely crushed metacarpals can be casted and early motion started at 3-4 weeks.

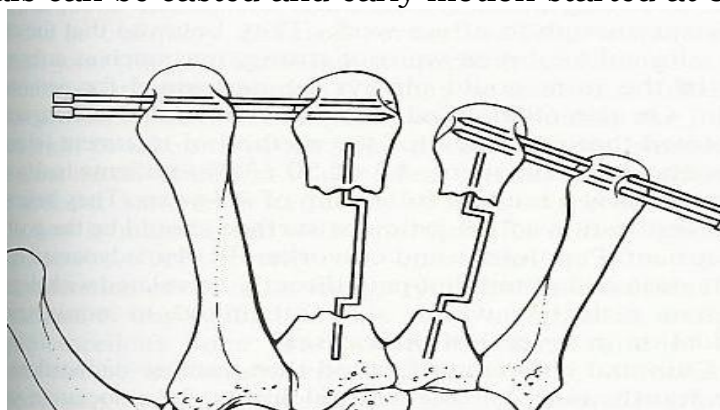


Fig 26

K-wires with right angle turns to maintain length when there is segmental loss. K-wires can be placed above and below with an “external fixator” as described above

◆ **Metacarpal neck or Boxer's fractures**

These are one of the more common hand fractures that generally result from the person striking an object in a longitudinal fashion with a closed fist. These generally result in apex-dorsal angulation. The amount of acceptable angulation is dependent upon the digit involved. As a general rule, the index and long finger can only tolerate 10 to 20 degrees of angulation. The commonly involved ring and small fingers can generally tolerate up to 50-60 degrees of angulation in metacarpal neck fractures. These fractures warrant an attempt at closed reduction in the acute setting with a hematoma block. The Jahss maneuver is used: Flex the MP joint while applying upward pressure through the proximal phalanx directed toward the metacarpal head. This can more easily be accomplished by flexing the PIPJ and pushing dorsal through the PIPJ. Care must be taken to prevent rotation of the metacarpal. This can be clinically achieved by comparison of the plane of the fingernails. Casts should include the wrist in slight extension, the MP joints flexed to 90° and the PIPJ extended. The PIPJ can be held in extension for two to three weeks and then allowed to flex. X-rays should be repeated at weekly for two weeks as these fractures are unstable.

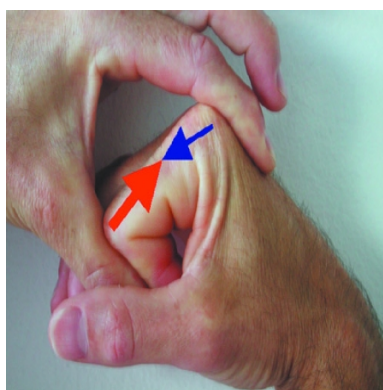


Fig. 27 Jahss Maneuver

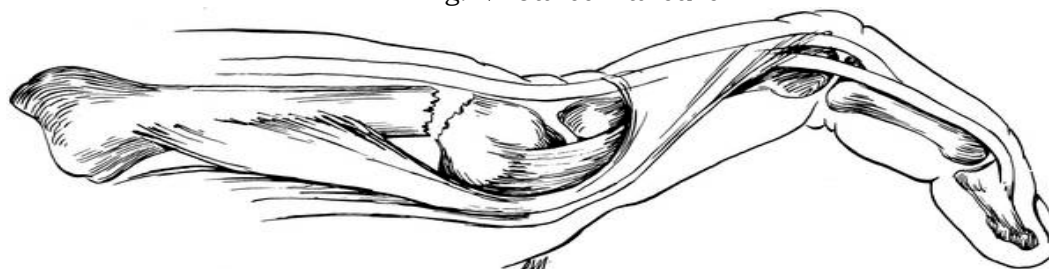

Fig 28

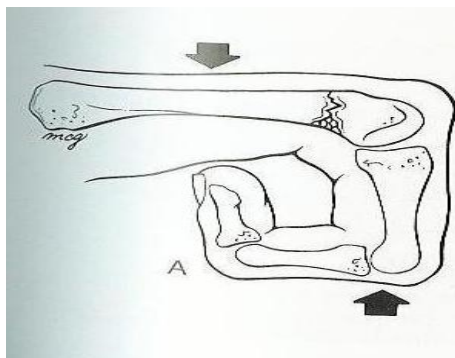


Fig 29

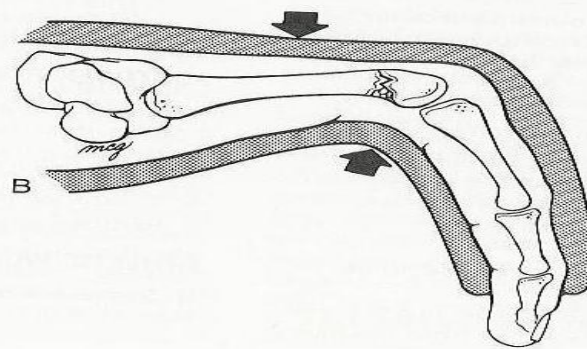


Fig 30

Fig 27-29 Metacarpal neck fracture: note dorsal angulation with head in palm.
Reduced by Jahss Maneuver and casted in position of protection
with MPJ flexed and IPJs extended

If the fracture is severely angulated (see Editor's Note below) and cannot be held in reduction with the cast, then attempted closed fixation with crossed K-wires through the MC head. The K-wires are placed from the either side of the head down into the proximal fragment. Alternatively, K-wires may be placed from the MC head into an adjacent stable MC head. A gutter splint is applied with the MPC's flexed, the PIP's extended for three weeks at which time range of motion is begun, and protective splinting continued for two to three more weeks. **Closed pinning will be difficult without fluoroscopy.**

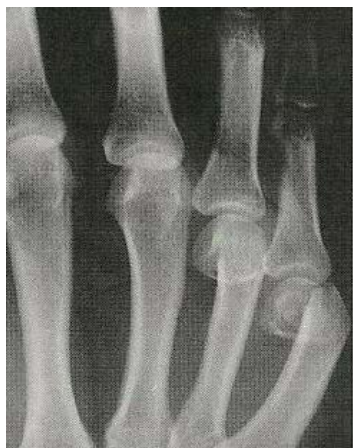

Fig 31

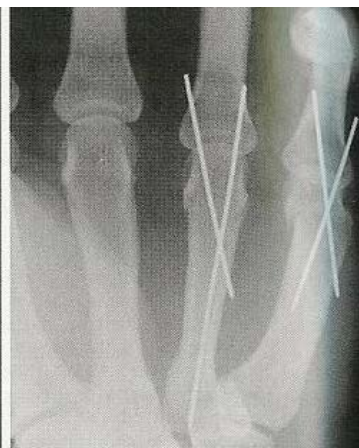

Fig 32

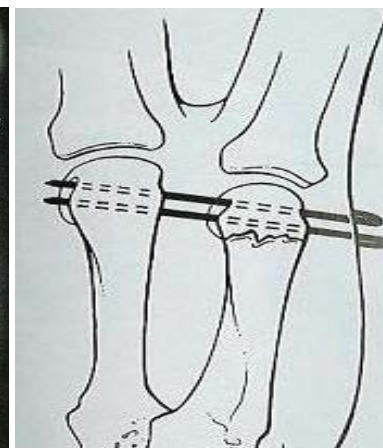


Fig 33

Metacarpal neck fractures: If necessary to pin (see below) these are two methods, crossed K wires through the MC head or K-wires from the fractured MC into the normal metacarpal while reducing the fracture with the Jahss maneuver. These methods are best done with a C-arm or portable x-ray.

(Editor's Note: Important Information--Some would only reduce these if the MC head was palpable in the palm or if there was pseudo-clawing deformity with extension of the proximal phalanx at the MP joint. Sometimes an angulation up to 75° will do fine and can be accepted.)

- ◆ (Gutter splint: a curved splint from dorsal to palmar around a border digit)
- ◆ **If the metacarpal neck fractures cannot be successfully reduced** and stabilized by closed methods, open reduction and percutaneous pinning may be necessary for significantly displaced/angulated fractures. This will be unusual, but untreated significantly angulated neck fractures in the index and long fingers that are left unreduced may cause significant pain in the palm. Open reduction is achieved through a longitudinal incision over the dorsal aspect of the affected metacarpal, retraction of the extensor tendon and longitudinal retrograde pinning through the metacarpal head. Pins are removed at 3 weeks and exercises begun. (The extensor tendons may be separated in midline to gain exposure, but this may lead to adhesions.)

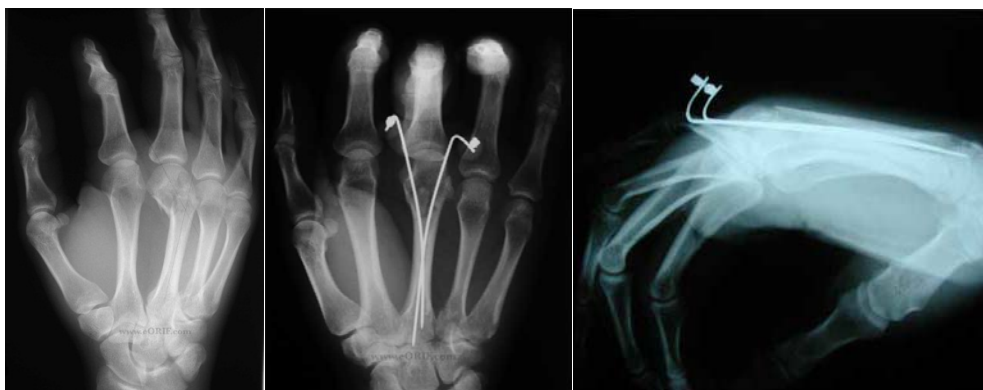

Fig 34

Fig 35

Fig 36

Angulation of third MC neck fracture with retrograde pinning:
Pinning was performed in this case since it was in the third metacarpal where the head in the palm is not as well tolerated.
(Courtesy of eORIF.com)

- ◆ Care must be taken to rule out an open fracture from a human bite wound.

Position of Protection: wrist slightly extended, MPJs flexed 80-90° and IPJs extended. This will prevent extension contractures of MPJ and flexion contractures of PIPJ.

- ◆ **Intraarticular fractures of the metacarpal head** require exact reduction if possible to maintain the metacarpal phalangeal joint. Minimally displaced articular fragments may be treated conservatively with protective splinting and careful early range of motion after 2-3 weeks. Closed reduction with molding and pinning of displaced intra-articular fragments can be attempted but if there is a residual 2-3 mm. step-off, these ideally require open reduction. Closed reduction and

pinning maybe tried on border digits. Open reduction can be accomplished via a curvilinear incision made over the MCP joint. A careful incision through the sagittal band leaving a cuff for later repair will provide good exposure to the joint surface. On occasion, the sagittal band and extensor tendon may be retracted with percutaneous pinning of the articular surface with small K-wires to achieve satisfactory stabilization. The MCP joint should be held in position of protection to maintain maximum collateral ligament length. Once again, great care must be taken to rule out human bite injuries.

(Editor's note: The above recommendations are somewhat theoretical. General surgeons in most district hospitals will find this open surgery difficult if not impossible. Therefore closed reduction and splinting in position of protection is maybe best with early range of motion exercises at 2-3 weeks. Splinting is continued for 6 weeks when not exercising. Stability and proper alignment of these fractures at the MPJ has been found to be more important than perfect articular reduction.

Special x-ray view: Brewerton for metacarpal head fractures— fingers on the film with palm up, MCP flexed 65°, and x-ray taken from 15° ulnar to the vertical.

Metacarpal phalangeal joint (MPJ) Dislocations:

Thumb

- ◆ Ulnar collateral ligament injury
 - ◆ This is the most common type of dislocation at the thumb MPJ and is secondary to a sudden radial deviation of the thumb at the metacarpal phalangeal joint with a tear of the ulnar collateral ligament. The ligament usually avulses from the base of the proximal phalanx. This injury is seen acutely but more often it is seen late and is known as a Gamekeeper's thumb. When seen late it is often associated with a Stener's lesion where the completely ruptured ulnar collateral ligament is found proximal to the adductor pollicis aponeurosis. When the aponeurosis is interposed between the ligament and the base of the proximal phalanx, the ligament cannot heal.
 - ◆ On exam there is swelling and if seen acutely there is tenderness and ecchymosis. When the joint is stressed radially, the joint is considerably more lax than the contralateral thumb. This test is best done with the MPJ flexed 30-40 degrees which limits the stabilizing effect of the volar plate in full extension. (When testing is done acutely, a local digital anesthetic block may be helpful to

relieve pain and give a better evaluation both for the clinical exam and stress x-rays as seen below.)

- ◆ X-rays should be taken to rule out a fracture at the base of the proximal phalanx.
- ◆ It is important to compare findings to the uninjured thumb.

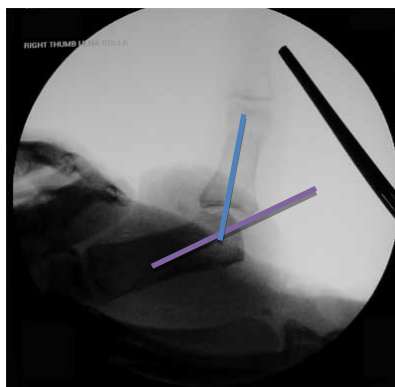


Fig 37

Stress view showing significant laxity of the thumb UCL
Note 40-45° angle (Courtesy of eORIF.com)

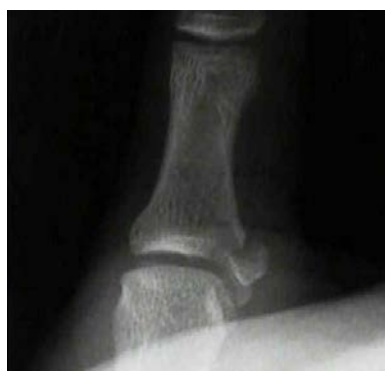

Fig 38

Avulsion ulnar base of thumb
proximal phalanx—Gamekeeper's thumb

- ◆ Indications for surgery:
 - If less than 30° laxity or less than 15° differential from the contralateral thumb when stressed, then acute injuries may be treated conservatively with a thumb spica cast with the MPJ slightly flexed for 4 weeks.
 - If greater than 30° laxity or greater than a 15° differential from the contralateral thumb, then operative repair is recommended.
 - Several surgical techniques have been described
 - If the patient is seen soon after injury then direct repair or repair using a bone anchor is possible

- For fractures at the base of the proximal phalanx, these will usually heal if not widely displaced and if casted for 6 weeks—or thumb spica splint. Otherwise open reduction is necessary with pins or preferably small screws.
- Chronic injuries can be repaired with either adductor advancement or a tendon graft
- One is referred to operative textbooks for description of these procedures.

(Editor's Note: It is recognized that in many of our hospitals these injuries, if recognized, will be treated with casting or splinting. If there is not a Stener lesion, the ligament/fracture will likely heal back. If one feels a mass over the proximal ulnar side of the MPJ, then a Stener lesion is probable and adequate healing of the ligament may not occur with splinting alone.)

Fingers

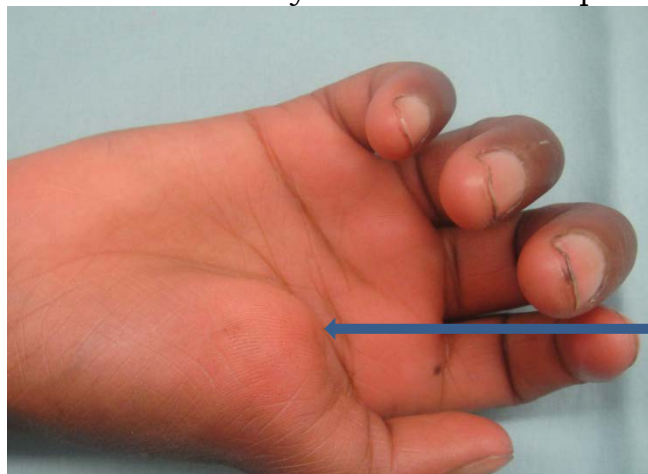
- Metacarpal phalangeal joint dislocations can occur either in a dorsal or volar position. Dorsal dislocations are much more common from forceful hyperextension and can be divided into simple and complex. These occur commonly in thumb and index finger.
- A **simple dorsal dislocation** is reducible when the phalanx remains in contact with the metacarpal head and the volar plate is not trapped within the joint.
 - These simple dislocations are usually quite obvious with significant angulation—more prominent than a complex dislocation.
 - Reduction is achieved by maintaining contact of the MCP joint while pushing the base of the proximal phalanx distally along the dorsum of the metacarpal.
 - Hyperextension or traction is not useful and is contraindicated.

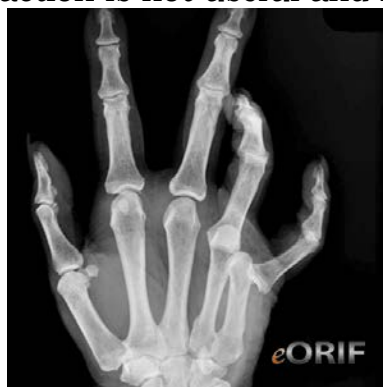

Fig 39

Simple dislocation of MPJ
(Courtesy of eORIF.com)

- ◆ **A complex dislocation** occurs when the volar plate ruptures from the metacarpal and becomes entrapped between the head of the metacarpal and base of proximal phalanx.
 - Puckering of the volar skin may be seen at the level of the metacarpal neck and this always indicates a complex dislocation.



Note "puckering"

Fig. 40

Complex thumb MPJ dislocation

- The proximal phalanx lies dorsally in the same direction as the metacarpal—"bayonet appearance."
- The metacarpal head is caught in a "noose" between the flexor tendons and the lumbrical muscles in the index and the flexor tendons and thenar muscles in the thumb.
- The volar plate is avulsed from the metacarpal and often trapped in the joint
- X-rays may show the sesamoid bones in a widened joint.
- Closed reduction is rarely successful and especially when the patient presents late.

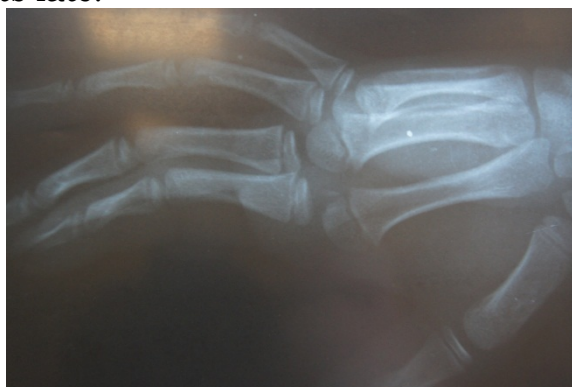

Fig 41

Complex dislocation of index MP joint with bayonet appearance: required open reduction. This dislocation could be easily missed

- Open reduction should be carried out from a **volar approach**.
 - This allows identification and protection of the radial digital nerve which is tented up next to the skin by the metacarpal head.
 - The flexor tendons are identified on the ulnar side of the metacarpal head and the A-1 pulley is divided. Usually this allows reduction.
 - In chronic cases that present late, a **dorsal approach** may also be needed to release the collateral ligaments from the metacarpal head and reduce the volar plate by splitting it in the midline and passing each side back around the metacarpal head.
 - The ligaments will reattach and do not need to be repaired.
 - The MPJ is held in 20-30° flexion for 2 weeks and then exercises are begun while the last 10° of extension is blocked.

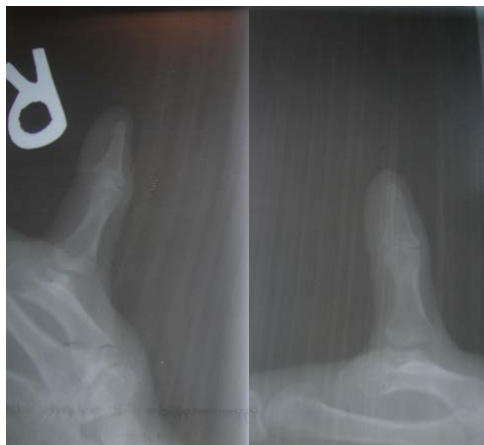

Fig 42 Fig 43
Chronic dislocation of thumb MPJ:
Required volar and dorsal approach

Phalangeal Fractures and Dislocations

- ◆ These are always serious injuries in those who use their hands from musicians to surgeons and to manual laborers. The flexor and extensor tendons lie close to the bone and are susceptible to injury and later stiffness.
- ◆ **Intra-articular fractures at the base** that are closed and minimally displaced can often be treated with manipulation, buddy-taping, and a dorsal splint with the MP joints flexed and early range of motion at 3 weeks. Significantly displaced with a 3 mm. step off or open intra-articular fractures (uncommon) can be opened through the dorsal

midline and pinned with small K-wires. However, stability and alignment are more important than a perfect articular reduction. If necessary and one has experience operating in this area, the extensor tendon is divided longitudinally in the midline or through the open injury. Approaching these laterally is possible if the fracture extends distally, but a lateral approach is difficult for fractures at the base of the proximal phalanx because of the lateral bands. One lateral band may be divided for exposure and then repaired at the end of surgery or sacrificed, but **this is difficult surgery** for the non-hand surgeon. If there is severe comminution, then a K-wire can be placed through the distal proximal phalanx or through the distal phalanx and traction applied. This pin can be incorporated into a cast while traction is placed on the MPJ. Traction should be discontinued and exercises begun at 3 weeks.

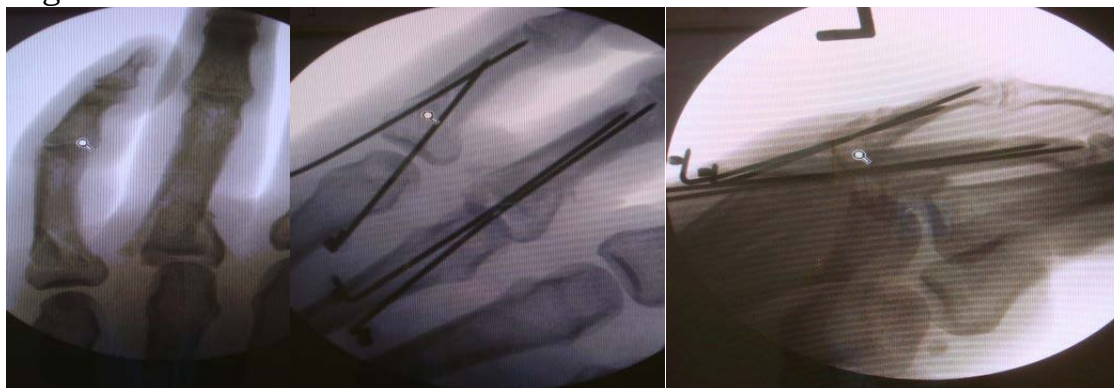


Fig 44

Fig 45

Fig 46

Base of proximal phalanx fractures: Treated by Eaton-Belsky technique below.
(Courtesy of Dr. Jason Rehm)

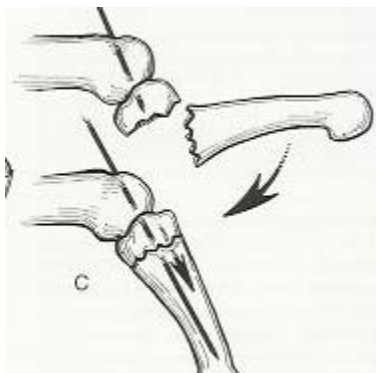


Fig 47

Eaton-Belsky technique: Pin through metacarpal head, fracture alignment, and pin passed into distal cortex of proximal phalanx

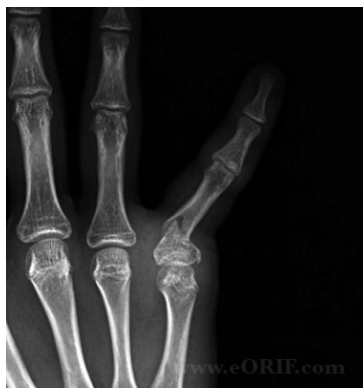

Fig 48 Base fracture—best treated with Eaton-Belsky technique

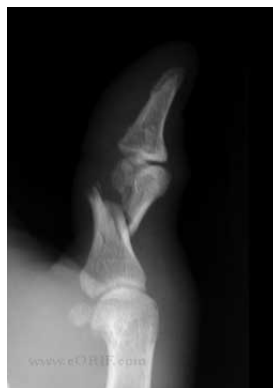

Fig 49

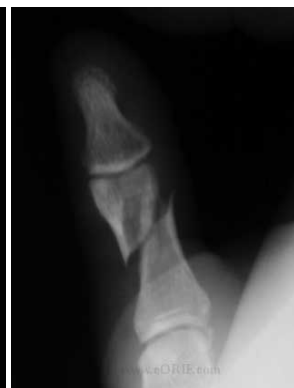

Fig 50

Shaft fracture—note apex volar angulation—Attempt Eaton-Belsky technique, otherwise treat closed in position of protection

- ◆ **Closed or open transverse fractures through the base or shaft of the proximal phalanx:** Proximal phalanx shaft fractures are most often have an apex volar angulation secondary to the volar flexion of the phalanx base by the intrinsic tendons and the extension of the distal end by the extensors at the central slip insertion. These can be best stabilized with flexion of the distal fragment and volar to dorsal pressure over the site of angulation so that it will line up with the flexed proximal fragment. If closed reduction is not stable with a cast, then the **Eaton-Belsky** pinning technique should be used. After the fracture fragments are reduced and aligned as best possible, two K-wires are passed through the metacarpal head and into the proximal phalanx with the MPJ flexed. The pins are inserted until resistance is reached at the distal cortex. This is excellent fixation for these fractures which should be attempted even if you do not have a C-arm. This procedure requires patience as one passes the K-wire through the metacarpal head and up to the fracture site, then through the distal fragment while manipulating it into reduction, and until resistance is felt distally. This technique gives rigid fixation as the fracture is stabilized proximally with the pin through the metacarpal head and distally by the pin engaging the distal cortex, but not into the PIP joint. If there is significant displacement, possibly from intervening soft tissue, or if the fracture is open, the Eaton-Belsky technique can be easily carried out under direct vision. These pins can be removed at 3 weeks and motion began. The PIPJ should never be splinted or casted in the flexed position. Proximal phalanx shaft fractures often lead to tendon adhesions.
- ◆ If a closed shaft fracture is displaced or rotated, then traction with manipulation, MPJ flexion, volar to dorsal pressure at the fracture site to correct the angulation and then splinting or casting with the PIPJ

extended will help align the fractures. The involved finger can be splinted together with the adjacent normal finger.

(Editor's note: If the Eaton-Belsky technique is not possible and closed reduction and casting/splinting does not result in perfect alignment, further exploration with open pinning or wiring of the fracture is NOT recommended unless the fracture is open. See below.)

- ◆ **Closed oblique or spiral fractures** of the proximal phalanx should NOT be opened unless severely displaced or open. If a closed fracture is displaced or rotated, then traction with manipulation, MPJ flexion, and volar to dorsal pressure at the fracture site will help align the fractures. Also the involved finger can be buddy taped and splinted together with the adjacent normal finger. These fractures often lead to both flexor and extensor tendon adhesions as the tendons are close to the bone. If there is shortening at the fracture site, an extensor lag at the PIPJ may result, but opening these injuries even with the ability to rigidly fix and even with good postop therapy will often lead to stiffness and loss of motion.

- ◆ **Open proximal phalanx** fractures should be irrigated and debrided and an attempt to stabilize with the Eaton-Belsky technique. This may be possible even with obliques and spiral fractures. With the pins in place the hand should be casted in position of protection with the PIP joints extended and immobilized. If this is not possible for transverse fractures, two small K-wires may be passed antegrade and obliquely from the fracture site through the medullary canal until they emerge laterally at the MC neck. When they penetrate the skin, they may be passed retrograde into the proximal fragment to hold the fracture. The wires are left through the skin distally for easy removal at 3 weeks. If stabilization of open spiral fractures is not possible with the above techniques, two or three K-wires may be placed transversely across fracture with or without a cerclage wire. Early motion with proximal phalanx fractures is much more important than rigid fixation. If the fracture is comminuted, external fixation as described above may be attempted.

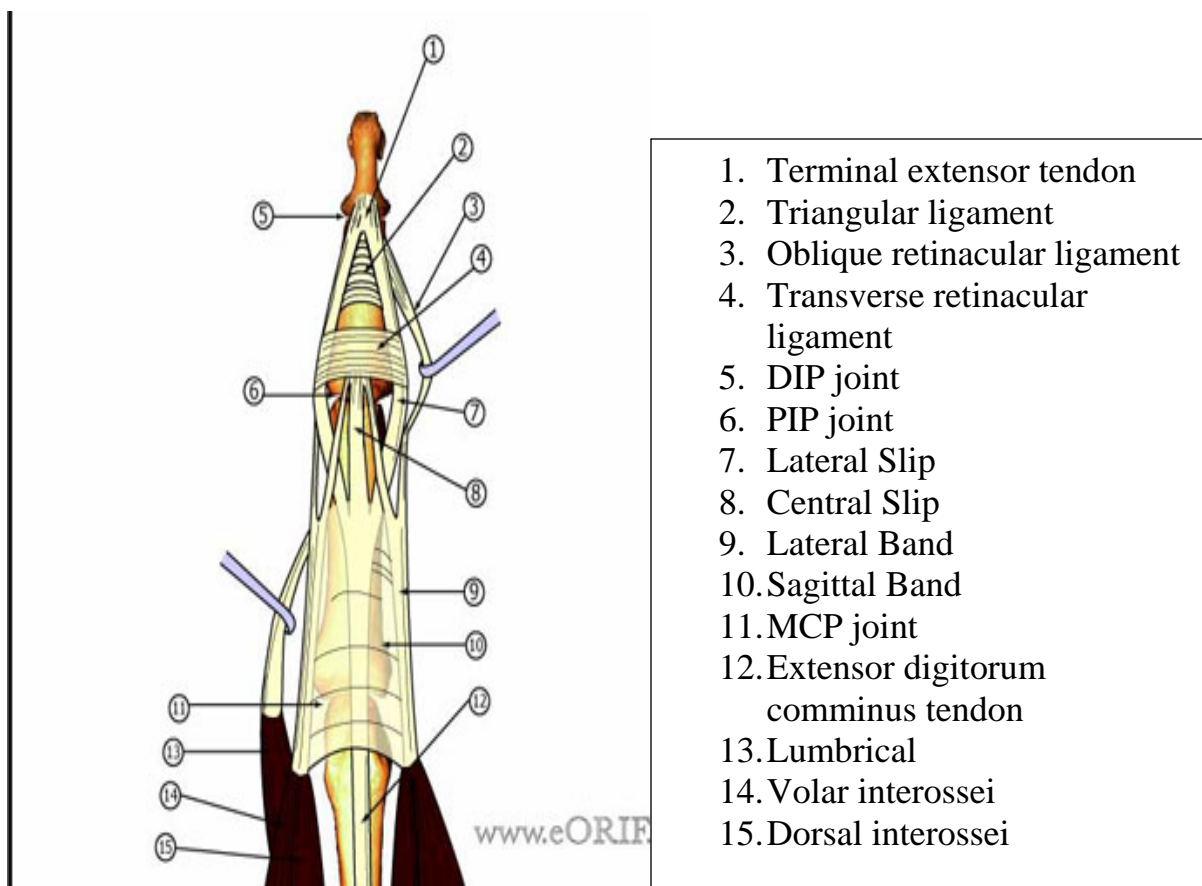


Fig 51

Note the close association of the tendons and the phalanges—this is the cause for adhesions and stiffness postoperatively and especially if the fracture is open or if open reduction is carried out. (Courtesy of eORIF.com)

- ◆ **Distal transverse condylar neck fractures in proximal or middle phalanges** are especially seen in children. These are dorsally displaced and sometimes rotated 90° with the articular surface pointing dorsally. These can be frequently missed, especially if a good lateral x-ray is not taken. Closed reduction can occasionally be accomplished early with traction and downward and distal pressure applied over the distal fragment. Since these fractures are unstable, once the fragments are reduced, K-wires should be placed through the head of the proximal phalanx into the shaft and left 4 weeks to maintain reduction. Because these fractures have little chance to remodel even in a child, open reduction may be necessary if closed reduction is not successful. A dorsal incision should be made and the fracture approached from below or volar to the lateral band. If the fracture involves the middle phalanx, after reduction a K-wire can be placed from the tip of the finger through distal phalanx and DIP joint and into the middle phalanx to hold the fragment reduced. The author has found 18-21 gauge hypodermic needles especially useful to pin these in children. The

needles can be easily twisted down the shafts of the bones for stabilization and one is usually sufficient.

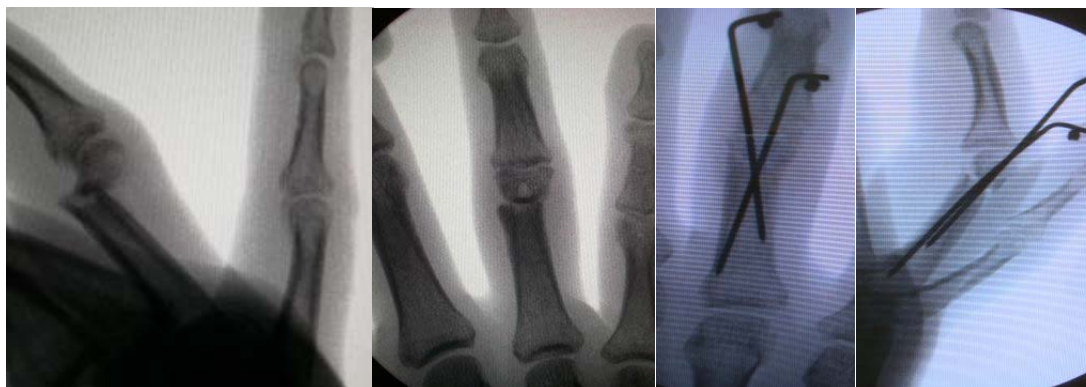

Fig 52

Fig 53

Fig 54

Fig 55

Condylar neck fracture, initially missed, required ORIF

- ◆ **Distal oblique intraarticular condylar proximal phalanx fractures** are difficult to treat when closed without a C-arm. While it is important to reduce and stabilize intra-articular fractures when there is a significant step off of 2-3 mm, rigid fixation is difficult without small screws. One potential closed method when there is a significant step off at the articular surface is to use one or more towel clips to attempt reduction. After x-rays are taken, a digital block is given in the x-ray department (or in the OR with a portable x-ray machine) and a towel clip is used to grasp each fragment and attempt to reduce the fracture fragments. Repeat x-rays are taken to visualize the reduction. Several attempts can be taken before opening the joint. If it must be opened, a dorsal incision is made, and the articular surface visualized through an incision between the lateral band and extensor tendon (central slip). A small towel clip can now be used under direct vision to approximate the fracture fragments. Once reduced closed or open, the fracture can be pinned percutaneously with two or three small 0.028 K-wires, depending on the length of the fracture. PIPJ surgery is not without complications whether opened or closed. If a fairly good closed reduction and fixation can be accomplished with manipulation, and a towel clip and K-wires, then this fracture may be casted or splinted closed with the MPJ in flexion and PIPJ in extension. Comminuted fractures should be treated in traction as described below.

PIP Joint Dislocations

- ◆ These are commonly seen and often poorly cared for. The most common dislocation is a **dorsal dislocation** with the middle phalanx dorsal to the proximal phalanx. They occur by hyperextension and axial loading.

- ◆ If there is a volar plate disruption at the base of the middle phalanx—without a fracture, then the dislocation can be reduced and held in 30° flexion for three weeks with a dorsal block splint and then 15° flexion for an additional two to three weeks. PIP joint flexion is allowed during this dorsal block splinting.

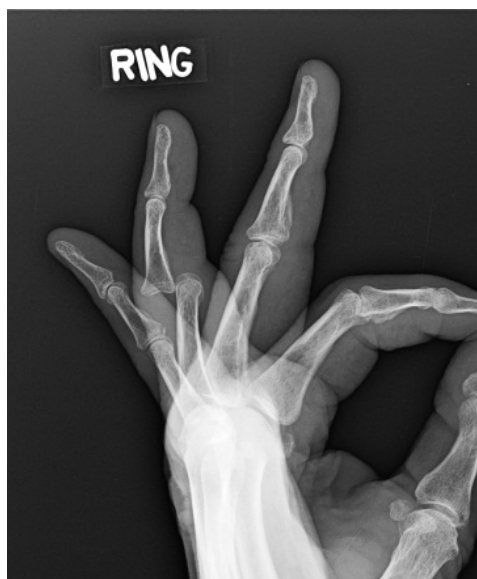

Fig 56
Dorsal PIPJ dislocation

- ◆ These dislocations often include a fracture of the volar lip of the middle phalanx which is attached to the volar plate.
- ◆ If this intra-articular fracture involves less than 40% of the articular surface, dorsal block splinting should be used. The collateral ligaments are still attached to the distal dorsal fragment and reduction is possible. This hand based splint holds the MPJ in flexion and the PIPJ in sufficient flexion to reduce the fragment—up to but not more than 40°.
- ◆ Patients must be closely followed and x-rays taken on a regular basis to ensure the reduction is not lost.
- ◆ The reduction should result in congruent dorsal articular surfaces of the phalanges. If there is a dorsal “V” shaped deformity on lateral views, then the reduction is not adequate.

(Editor’s note: Excellent technique below: (courtesy of Dr. Bill Bourland)—this technique will require some x-ray control, either a C-arm or portable x-ray: “Hyperextend the PIP and drive a 0.035 K-wire under the volar fracture lip fragment (from the volar side) through the proximal phalanx and withdraw it dorsally until the volar pin just blocks the volar lip fragment. Then flex the PIP joint until the dorsal fragment reduces with the volar pin preventing the volar lip fragment from moving. Then drive a 0.035 K-wire dorsal to the dorsal lip of the middle

phalanx into the proximal phalanx. Cut the pins beneath the skin. Splint for three weeks. Remove the pins under local and begin protected ROM with a dorsal blocking splint.”

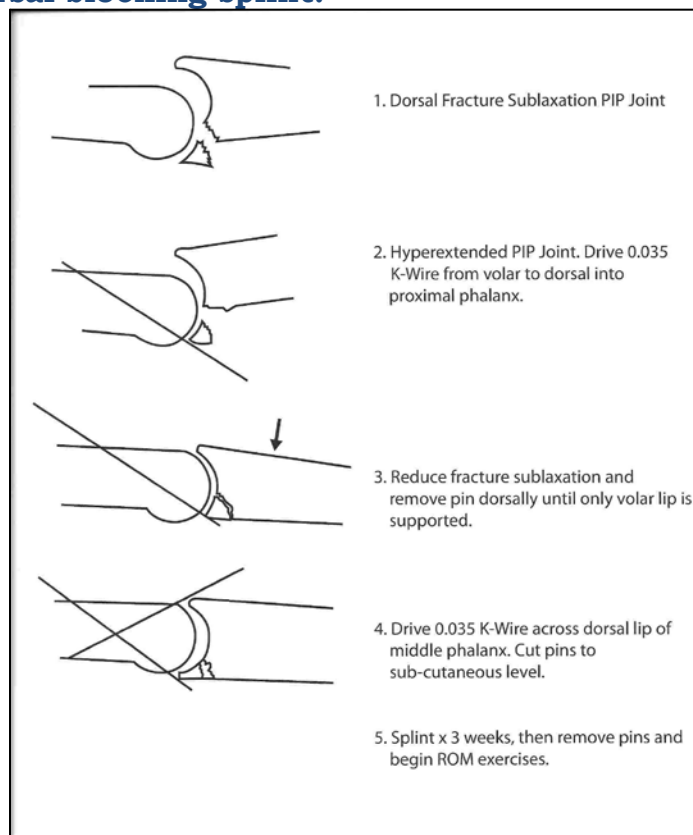


Fig 57

Treatment for fracture-dislocation of PIPJ
(Courtesy of Dr. Bill Bourland)

- ◆ When the middle phalanx fracture fragment involves greater than 40-50% of the articular surface, dorsal block splinting will not work. The collateral ligaments are no longer attached to the dorsal distal fragment and closed reduction will not be stable. The angle of the dorsal block would have to be increased and this would lead to a stiff, flexed PIPJ.
- ◆ In these situations, when a dorsal block splint is unsatisfactory, then open reduction or an external traction is necessary. The editor would attempt the technique above.
 - A volar and sometimes a “shot gun” approach is best as it gives good visualization of the fracture fragment and attached volar plate, **though it requires some experience and knowledge of anatomy around the PIPJ.**
 - A volar zigzag incision (Bruner) is made across the PIPJ. Care is taken to identify and not damage the neurovascular bundle on either side. The A-3 pulley is divided and the flexor sheath

opened from A-2 to A-4 pulleys. The flexor tendons are retracted to one side and the joint inspected.

- If better exposure is necessary, the collateral ligaments may be divided at their origin and the joint opened with hyperextension (shotgun approach). Once the volar fragment is reduced, small K-wires may be placed obliquely across the fragment into the middle phalanx. If the fragment is small or comminuted, another technique involves passing a suture/small steel wire through the volar plate at its insertion into the avulsed fragment and then passing the suture/wire through a drill hole in the middle phalanx and twisted down. With either technique, the joint should be immobilized in slight flexion for 3 weeks. K-wires should be removed at 3 weeks and gentle ROM exercises carried out. The collateral ligaments will reattach and do not need to be repaired.

(Editor's note: PIPJ surgery is difficult. I recommend splinting and early range of motion or traction with pins above and below the PIPJ for fracture dislocations involving > 40% of the articular surface. The "shotgun" approach above is difficult even for the accomplished hand surgeon and stiffness will result no matter the how accurate the reduction and fixation.)

- ◆ **Volar dislocations** are the result of a rupture of the central slip or a dorsal lip fracture with the central slip attached to the fragment. If an extensor tendon/central slip avulsion, this may be treated closed or open with repair of the central slip insertion. The easiest treatment is placing a pin through the PIPJ to hold it in extension for 6 weeks. If the fragment is large and the reduction is not stable, then an open approach may be carried out with pinning of the fragment to the middle phalanx with one or two small K-wires and with an additional K-wire through the PIPJ to ensure compliance in keeping the PIPJ extended at 0°.
- ◆ **Rotatory dislocations** are rare but also possible. These may be looked up in a major text.
- ◆ **Comminuted fractures** in jammed fingers at the base of the middle phalanx are also frequently seen—a pilon fracture. These occur with significant axial loading and include both dorsal and volar lip fractures with a destroyed middle phalanx articular surface. In district hospitals these injuries should be treated with splinting and early range of motion. If one has significant experience in hand surgery, one may try the dynamic PIPJ traction method shown above.

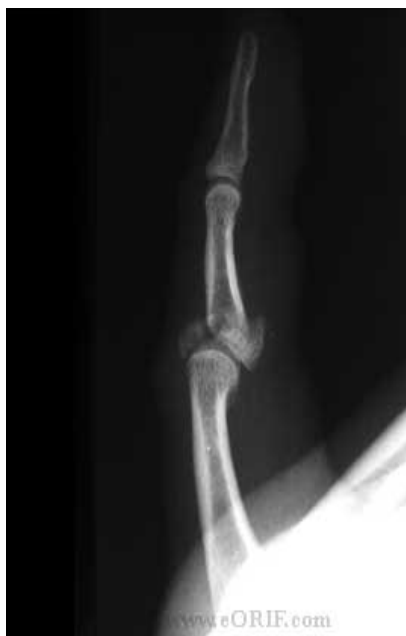

Fig 58

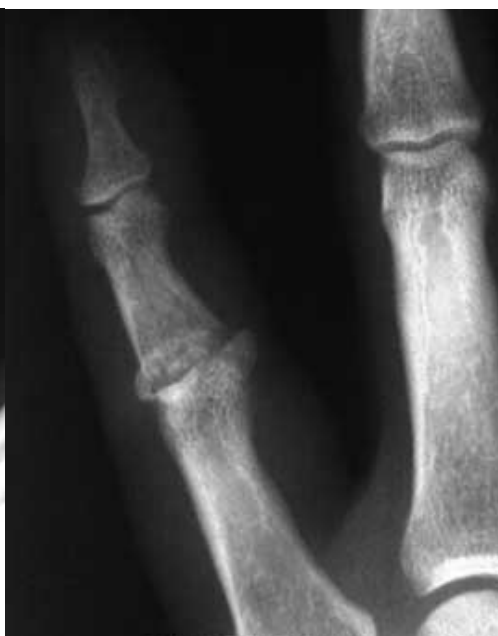

Fig 59

Pilon fracture dislocation of PIPJ (Courtesy eORIF.com)

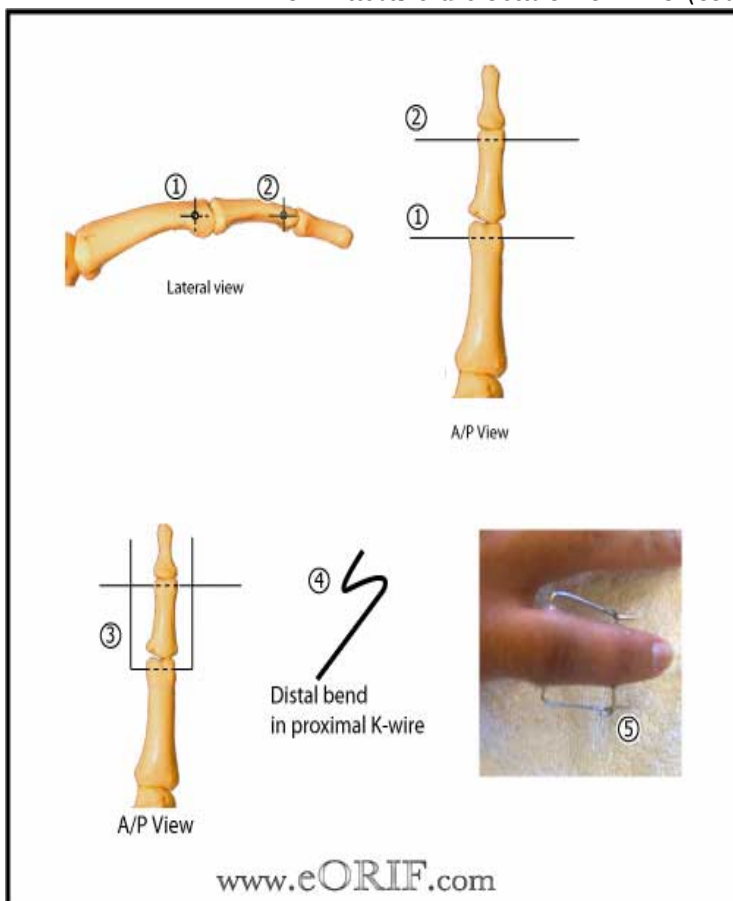


Fig 60 Method of dynamic PIPJ external fixation for traction (Courtesy eORIF.com)

(For dynamic fixator technique: see [Ruland RT, J Hand Surg 2008; 33:19](#))

Treated with dynamic PIP joint external fixation ([Badia A, J Hand Surg 2005; 30A:154](#))

1. 0.045in K-wire placed transversely through center of the head of the prox phalanx
2. 0.045in K-wire placed through center of the head of the middle phalanx
3. Proximal K-wire is bent 90 degrees to be parallel to middle phalanx
4. End of proximal phalanx K-wire is bent >90 degrees dorsally and again >90 degrees volarly to make S configuration at tip
5. Traction applied and distal K-wire is engaged and bent 90

Unfortunately, no matter what the treatment is for these PIPJ injuries, arthritis and stiffness will likely be a final result.

Middle Phalanx Fractures

- ◆ Closed shaft fractures are rare and most will be treated closed with early range of motion. If opened and fixed significant stiffness will result. These should only be treated open when there is an open injury. Intra-articular fractures through the head of the middle phalanx may be treated as for the proximal phalanx but a stiff joint will likely result regardless of the technique.

Distal Phalanx Fracture/Dislocations

- ◆ Most common these are apex dorsal dislocations of the DIPJ—**Mallet finger**. These can be tendinous with an avulsion of the extensor tendon or bony with a fragment of the dorsal lip of the distal phalanx avulsed off with the tendon. Tendinous injuries are best treated with a K-wire to hold the DIPJ in extension for 6 weeks followed by splinting in extension for another 6 weeks while allowing gradual increase in exercises during the day but constant splinting in extension at night. Bony avulsions if less than 50 % of the joint surface may be treated the same way. Some would pin the dorsal lip fragment for >50% of the joint surface involved while many would continue with the closed pinning in extension. An excellent technique to reduce and hold this dorsal lip fracture is with the insertion of the K-wire through the distal extensor apparatus into the distal dorsal articular surface of the middle phalanx while the DIPJ is held in flexion. (See figure below.) The distal phalanx is then extended and pinned in extension. The “extensor block pinning” allows the fragment to be reduced and held in reduction by the pins. This avoids causing potential comminution of the fragile fracture fragment when attempting to insert a K-wire directly into the fracture fragment. These dorsal lip fractures may be comminuted. Splinting the DIPJ alone may be used but compliance is a major factor. Without treatment there will be an extensor lag with subluxation of the volar fragment, but this is only of cosmetic importance as it rarely will affect function.

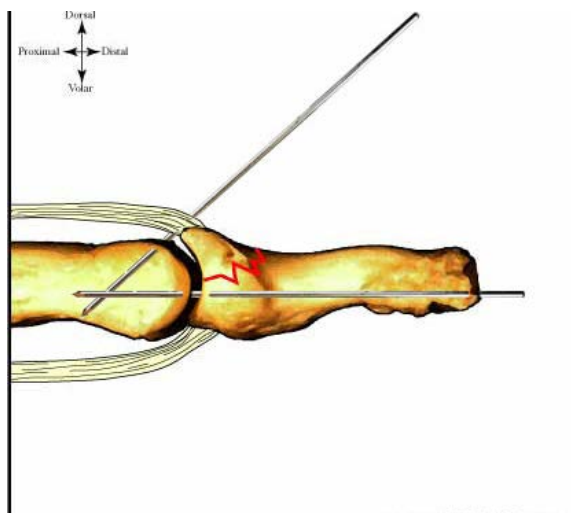


Fig 61
See actual method of fixation below.
(Courtesy eORIF.com)

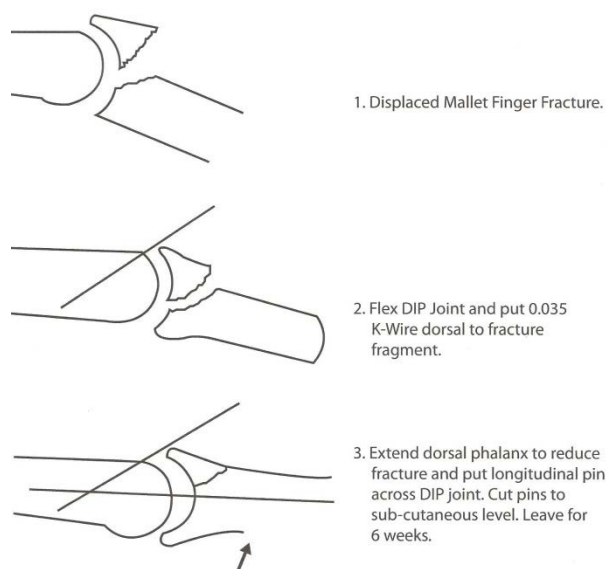


Fig 62
Extensor block splinting for bony Mallet fracture-dislocations:
The pin through the middle phalanx is inserted first with DIPJ in flexion.
Distal phalanx is then extended and a pin passed from the distal tip of the
distal phalanx into the middle phalanx. (Courtesy of Dr. Bill Bourland)

Epiphyseal fractures

- ◆ These occur in 5 types and the classification can be found in major texts. The author would treat all these closed with fracture manipulation and reduction except the grossly displaced or angulated.

If acceptable reduction cannot be accomplished, then open reduction and pinning can be carried out. If possible reduction and pinning with a portable x-ray machine in surgery or in the x-ray department would be better than opening these fractures in children. Open epiphyseal fractures are rare. One important epiphyseal fracture not to be missed is the dorsal angulation fracture at the base of the distal phalanx, so-called Seymour fracture. This occurs through the nail bed which should be repaired after the fracture is reduced and pinned. One must ensure that the nail bed is not trapped in the fracture site. A #18-#21 hypodermic needle may be used to pin this fracture with the pin passed from the tip of the finger into the middle phalanx.

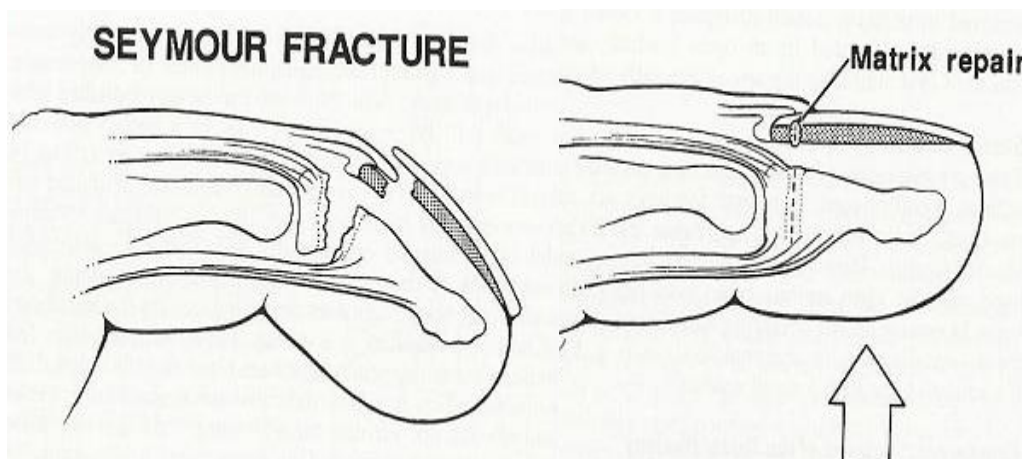


Fig 63 Seymour fracture through epiphysis of distal phalanx

- ◆ It is important to take x-rays of the opposite normal hand with all questionable fractures, especially epiphyseal fractures in children.

Final Thought

Bottom Line: Most closed hand fractures, up to even 90%, will do well if recognized and treated with an appropriate cast or splint—CLOSED!