

# Conceptual origins, current practice, and views of wide awake hand surgery

Donald H. Lalonde

Journal of Hand Surgery  
(European Volume)  
2017, Vol. 42(9) 886–895  
© The Author(s) 2017  
Reprints and permissions:  
sagepub.com/journalsPermissions.nav  
DOI: 10.1177/1753193417728427  
journals.sagepub.com/home/jhs



## Abstract

This article reviews historical background, essential practice principles, and the new emerging area of wide awake hand surgery. It outlines the reasons that wide awake, local anaesthesia, no tourniquet surgery has emerged so quickly in the last 10 years over the world. I explain the origin of the concepts and some of the challenges of getting the technique accepted; in particular, the debunking of the myth of epinephrine danger in the finger. I review the most recent developments in several operations in this rapidly changing field of the tourniquet-free approach. Finally, this review includes speculations on the future of this technique.

## Keywords

Wide awake, WALANT, finger epinephrine, no tourniquet, phentolamine rescue, pulley venting

Date received: 14th July 2017; accepted: 30th July 2017

## Introduction

Wide awake, no tourniquet, no sedation hand surgery, is all about making hand surgery as simple as a dental procedure. Only lidocaine with epinephrine are injected in a tumescent fashion directly into the area of surgery. Tumescent means enough local anaesthesia that it is visible and palpable wherever dissection or bone manipulation will occur. This is like an extravascular Bier block, but only where it is needed to eliminate pain and decrease bleeding. There is no intravenous insertion, no monitoring, no routine preoperative testing, and no fasting. This technique is known as WALANT (wide awake local anaesthesia no tourniquet). It can be performed in the outpatient setting or office with field sterility with safety (Leblanc et al., 2007).

## Historical background of challenges to wide awake hand surgery

### *Low risk of injection of epinephrine*

The main challenge to pure local anaesthesia and getting rid of the tourniquet was the myth that epinephrine injection in the finger commonly led to necrosis. 'Never inject epinephrine into fingers, nose, penis and toes'. Even the person who came last in every medical school class easily remembered this mythical rhyme.

Several observations made it obvious to me as a medical student in 1975 that this dogma could not be true. I watched our Queen's University hand surgeon, Dr Patrick Shoemaker, routinely inject epinephrine in fingers to do wide awake flexor tendon repairs. Dr Robert MacFarlane, of Dupuytren's fame and past president of American Society for Surgery of the Hand, also routinely did his finger surgery with epinephrine. Most hand surgeons in Ottawa were routinely using epinephrine in the finger. All Canadian plastic surgeons were routinely using epinephrine in the ears and nose. There was a major disconnect between the reality of what was safely being done and what I was reading.

In the year 2001, Keith Denkler (2001) published a landmark article of 120 years of literature review of only 48 cases of finger death attributed to local anaesthesia, with not one case involving lidocaine with epinephrine. That article ultimately led us to publish the true cause of the epinephrine myth (Thomson et al., 2007). Before 1948, when lidocaine became available, the epinephrine myth was born.

---

Dalhousie University, Saint John, NB, Canada

### **Corresponding Author:**

Donald H. Lalonde, Dalhousie University, Suite C204, 600 Main Street, Saint John, NB E2K 1J5, Canada.  
Email: drdonlalonde@nb.aibn.com

In that period, the only local anaesthetic was procaine. Denkler discovered that more fingers necrosed with procaine alone than when epinephrine was added to the procaine. There were no expiry dates before 1972. Procaine left on the shelf turned acidic to a pH of 1 (Food and Drug Administration, 1948; Thomson et al., 2007). Procaine necrosed the fingers and epinephrine got the blame. The epinephrine vasoconstriction rescue agent, phentolamine, was invented in 1957, long after the epinephrine myth was well cemented by Bunnell's 1944 book of hand surgery (Bunnell, 1944).

Spurred on by Denkler's 2001 article, the knowledge that so many of my mentors could not be wrong, and the fact that phentolamine could rescue epinephrine vasoconstriction, I decided to use epinephrine in every finger case with good preoperative refill in the fingertip until I needed phentolamine rescue. I still have not needed it and I have not had a single case of finger necrosis in well over 2000 cases.

In 2003, we published level I evidence that phentolamine reliably reversed epinephrine in the human finger. In this article, 18 Dalhousie University hand surgeons (including Dr Don Lalonde) had two fingers injected three times each with epinephrine and then one finger injected with phentolamine (Nodwell and Lalonde, 2003) (Figure 1). In 2005, we published over 3100 consecutive cases of elective finger and hand safe epinephrine injection cases by nine surgeons in six cities with no requirement for phentolamine rescue (Lalonde et al., 2005). Dr Jin Bo Tang and his colleagues in China have performed over 5000 cases in the last 3 years without one case of necrosis (Tang, 2017). In 2007, we reviewed all the accidental 1:1000 epinephrine finger injections; none suffered necrosis (Fitzcharles-Bowe et al., 2007). These early publications led others to chime in with

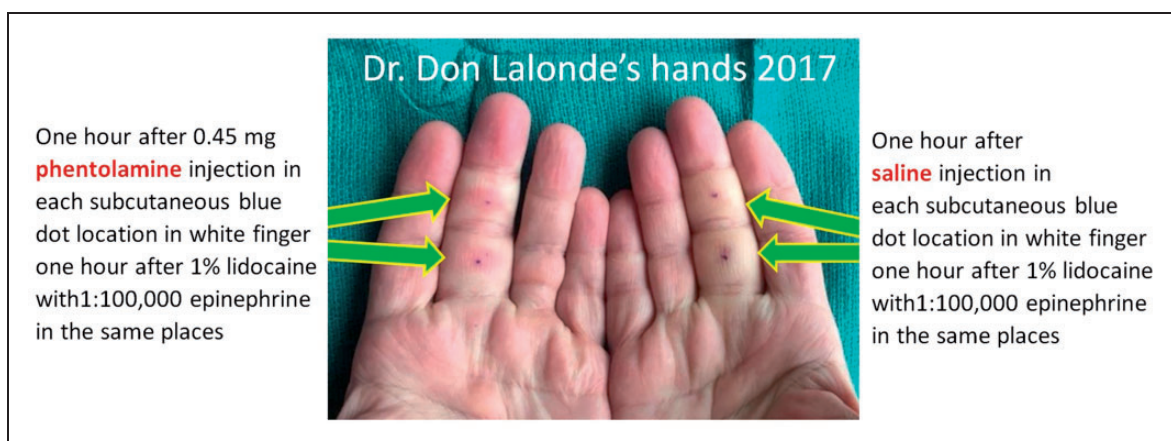evidence that finger epinephrine is indeed safe (Chowdhry et al., 2010; Mann and Hammert, 2012; Muck et al., 2010).

Surgeons still need to be careful that patients may attribute finger loss to epinephrine when they attempt to 'get their feeling back' by submersing their fingers in excessively hot water and suffer burn injuries (Zhang et al., 2017). Denkler reported 14 such cases (Denkler, 2001). Hot water burns are the most common cause of finger loss attributable to local anaesthesia. The images of two (Hutting et al., 2015; Ravindran, 2012; Ruiter et al., 2014; Zhang et al., 2017) of the five recent cases (Sama, 2016) of digital necrosis associated with lidocaine and epinephrine in the literature look like they could have been burns. Careful study reveals that none of the five cases are convincingly caused by the epinephrine. None of the five cases were treated with phentolamine rescue, which is the appropriate therapy if epinephrine is involved in ischemia (Nodwell and Lalonde, 2003). It is prudent to always have the phentolamine rescue agent on hand (Zhu et al., 2017).

Other challenges to implementing wide awake hand surgery are mostly custom or system issues: 'We have never done it this way'. 'We feel that our patients need sedation'. 'They don't want us to do surgery in our operating rooms without sedation'. 'Our anaesthesiologists are blocking this'. As more and more patients realize that wide awake hand surgery is easier than a visit to the dentist, the traditional tourniquet/sedation route will be increasingly challenged.

### Main benefits of WALANT

Major benefits for the patients of performing wide awake hand surgery include the following. (1)



**Figure 1.** To reverse a white finger, inject 0.45–2 mg wherever the epinephrine was injected and the skin will pink up in 1 hour. In the hands shown here, a total of 1.5 mg was injected 1 hour before this photo was taken to reverse the left white finger. The right white finger became pink in 5 hours without phentolamine.

No nausea, vomiting, urinary retention, and other unwanted side effects of opiates or sedation. (2) Patients do not need to endure unnecessary tourniquet pain, even for 5 minutes. No tourniquet is also very helpful in patients with lymphedema or arteriovenous shunts. (3) Hand surgery under pure local anaesthesia is much less expensive than with sedation, so many more can afford it. (4) Patients do not have to pay for a baby sitter or take time out of work to get preoperative testing. (5) WALANT is safer for patients than sedation, especially those with medical comorbidities (Husted et al., 2017).

All anaesthesiologists agree that less sedation is safer than more sedation. The safest sedation is therefore no sedation. Consequently, (1) patients spend less time at the hospital for the procedure, as there is no recovery time; (2) they do not need anyone to stay with them the evening of the surgery; (3) they get to know and talk to their surgeon during the local anaesthesia injection and during the surgery for advice on how to avoid complications, when to return to work, and how to take pain medication; (4) there is no need for preoperative anaesthetic assessment visits, chest X-ray, and needles for blood tests – intravenous needle insertion pain also disappears; (5) all they need to feel is a single poke with a 27- or 30-gauge needle in the hand when local anaesthesia is injected with minimal pain technique (Lalonde et al., 2016a); (6) they get to see their repaired tendons, bones and fingers work during the surgery after tendon laceration, tenolysis, tendon transfer, hand fracture, or Dupuytren's contracture. Seeing their repaired hands move during the surgery helps motivate them in postoperative therapy and recovery; (7) they do not need to fast or change medication schedules, which is particularly helpful in diabetics; (8) patients with sore elbows, shoulders, or backs can position themselves comfortably and shift to more comfortable positions during the surgery because there is no tourniquet or anaesthesiology equipment – they can easily turn on their side; (9) patients do not need to suffer the humility of undressing for hand surgery when we use field sterility, (10) there is no need to discontinue anticoagulation medication with epinephrine vasoconstriction.

In addition, it is much simpler to see a patient in consultation and operate on them the same day. This is very convenient for patients who travel far (Rhee et al., 2017).

Major benefits for the surgeons include the following. (1) The surgeons only need one nurse to perform most simple hand operations, such as carpal

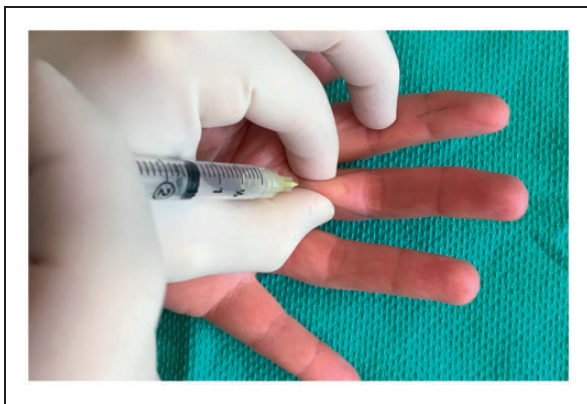
tunnel, trigger finger, and de Quervain releases. This greatly increases efficiency and reduces cost. (2) Surgeons can do many more simple cases in the same amount of time with procedures moved out of the main operating room to the office or minor procedure room. (3) They are able to operate on patients with multiple medical problems safely and easily, as those patients only get lidocaine and epinephrine as they do at a dental visit. (4) Surgeons are less likely to operate on the wrong hand or the wrong finger if the patient is wide awake with no sedation. (5) They get to make adjustments on repaired tendons, ligaments, and bones after seeing active movement in comfortable cooperative patients during the surgery. Surgeons make sure everything is functioning well before they close the skin. Patients help rupture adhesions in tenolysis. (6) Surgeons can set proper tension in tendon transfers before they close the skin by watching the patient test the tension by actively moving the transfer. (7) They do not have to look after admitted patients forced into hospital after hand surgery because of sedation or general anaesthesia complications or concerns. (8) Tourniquet let down bleeding with the time and expense needed for cautery is avoided in most cases, as the bleeding dries up with epinephrine by the end of the case. (9) Surgeons can use local anaesthetic injection and operative time to educate the patient for better outcomes and fewer complications. Time spent on intraoperative patient education can decrease time spent in the office; surgeons are more likely to get better patient compliance when they personally tell the patient to keep the hand elevated and immobile at the end of the surgery. (10) Surgeons can do hand trauma, such as tendon repair and finger fracture Kirschner (K)-wiring during the day in minor procedure rooms instead of in the middle of the night in the main operating room. They are more likely able to do better surgery when they are rested during the daytime than at night.

### **Basic approaches and current application**

The three most important technical points are: (1) read the articles on how to eliminate the pain of the injection of local anaesthesia (Lalonde et al., 2016a; Strazar et al., 2013); (2) invest the small time it takes to learn about how to properly inject local anaesthesia for the different hand operations (Lalonde, 2016a; Lalonde et al., 2016b; Lalonde and Wong, 2013); (3) be ready to inject 0.5–2 mg of phentolamine to reverse epinephrine vasoconstriction in the rare circumstance that you may require it (Lalonde, 2016c; Zhu et al., 2017).

### Minimize the pain of local anaesthetic injection

To decrease the pain of local anaesthetic injection do the following. (1) Use small needles such as 27 gauge. Use 30 gauge to start in children or apprehensive patients. (2) Buffer acidic 1% lidocaine with 1:100,000 epinephrine with 8.4% bicarbonate in a 10ml:1ml ratio (Frank and Lalonde, 2012). (3) Stabilize the syringe with two hands with the thumb ready on the plunger before inserting the needle so the patient does not feel needle wobble as the needle insertion site is numbing. (4) Pinch the skin into the needle instead of pushing the needle into the skin (Figure 2). If there is not enough skin to pinch,

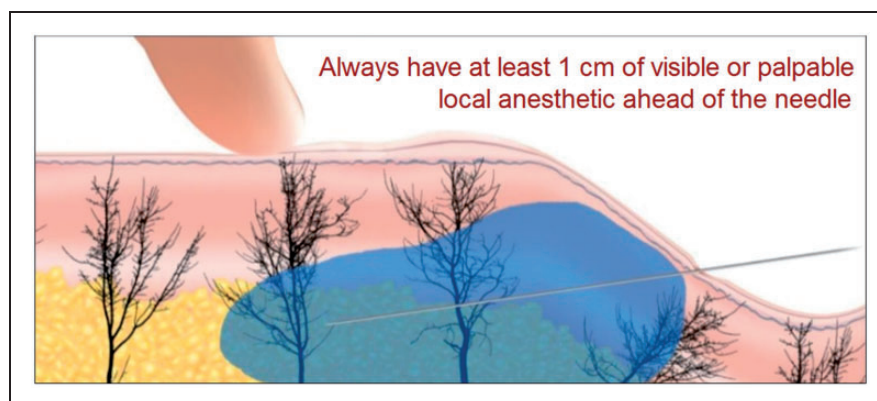


**Figure 2.** Pinch skin into needle when injecting no more than 2 ml in the subcutaneous fat for a SIMPLE finger block, pinch the skin three times. On the third pinch, the skin is actually pinched up into the needle which is just above the skin as it rises. The sensory noise of touch, pressure, movement, and pinch drown out the pain noise so the patient barely feels the 27- or 30-gauge needle poke. SIMPLE stands for single *subcutaneous injection in the middle of the proximal phalanx* with lidocaine and epinephrine. Do not inject in the flexor sheath as it hurts more.

press firmly on the skin just proximal to the needle insertion site for sensory noise. (5) Insert the needle perpendicular to the skin instead of parallel to it. (6) Inject under the dermis instead of in the dermis. (7) Inject the first 2–3 ml very slowly without moving the needle at all. (8) Always make sure you have at least 1 cm of visible or palpable local anaesthesia ahead of your sharp needle tip (Figure 3). (9) Inject antegradely and generously so you see and feel the tissues expanding ahead of your needle as you slowly advance it. (10) When reinserting the needle, reinsert it inside 1 cm of vasoconstricted white skin swollen with local anaesthetic so you never reinsert a needle in sensate skin (Figure 3). (11) Always inject from proximal to distal as the nerves run that way. The goal is to get a 'hole in one' every time. This means the patient only feels the tiny poke of a 27-gauge needle and no other pain during the whole injection.

### How much volume to inject?

Be generous with local anaesthetic volume. It is better to have way too much than not enough, as long as we keep a safe total dose. Tumescence local anaesthesia means enough local anaesthesia that you can see it and feel it bulge under the skin. Inject enough volume so that there is tumescence at least 1–2 cm beyond anywhere you will have a painful stimulus. Most of the world uses the 1948 generated 7 mg/kg of lidocaine with epinephrine upper limit of safe dosage. We now know that this dose is ridiculously safe as there are articles and large clinical experiences in liposuction showing safe lidocaine blood levels with up to 35 mg/kg (Burk et al., 1996; Klein, 1990). This is why 7 mg/kg is very safe without monitoring. That means 50 ml of 1% lidocaine with 1:100,000 epinephrine. If I need less than 50 ml for adequate tumescence, I use undiluted 1% lidocaine with 1:100,000 epinephrine. If I



**Figure 3.** Never advance the sharp needle tip into an area that is anaesthetized to avoid unnecessary painful injection.

need between 50 and 100 ml, as in trapeziectomy or cubital tunnel release, I add 50 ml of saline to 50 ml of 1% lidocaine with 1:100,000 epinephrine. If I need 100 to 200 ml of volume for adequate tumescence, such as in forearm tendon transfers, I add 150 ml of saline to 50 ml of 1% lidocaine with 1:100,000 epinephrine for very effective anaesthesia and haemostasis, even at this reduced concentration.

### *How long to wait and how long does it last?*

It takes about 30 minutes for epinephrine vasoconstriction to decrease bleeding optimally (McKee et al., 2013). For this reason, we inject patients on stretchers outside the operating room to give time for epinephrine and lidocaine to work well. We inject three carpal tunnels before we do the first one, then inject the fourth before we do the second one, etc.

We have up to 2.5 hours of good reliable local anaesthesia with the tumescent fluids described above, so longer acting more dangerous anaesthetics, such as bupivacaine or ropivacaine, are not usually necessary to add in small doses unless we are doing complex forearm tendon transfers, or painful procedures such as trapeziectomy.

## **Recent important advances in wide awake hand surgery**

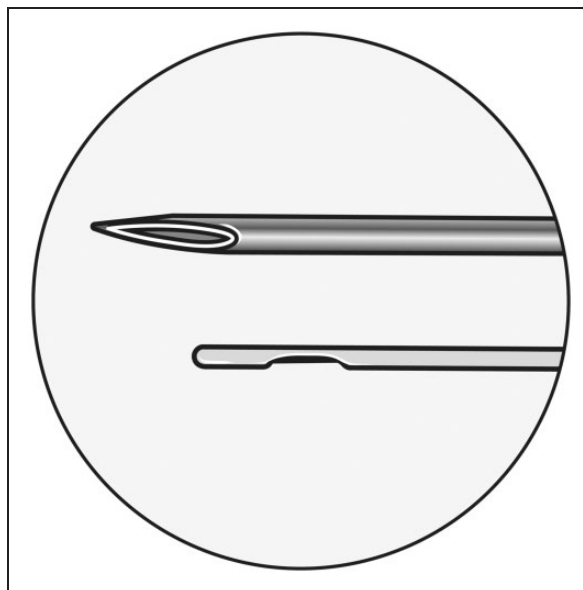
### *Improvements in local anaesthesia injection*

The first of two main improvements is that anyone can inject tumescent local anaesthesia to large areas of the hand and forearm with minimal pain. All the patient needs to feel is the initial poke with a 27- or 30-gauge needle (Strazar et al., 2013). Detailed videos and illustrations are available in the chapter of Lalonde et al. (2016a). The technique can be easily learned by students and residents (Farhangkhoe et al., 2012).

The second is the advent of blunt tipped flexible metal cannula injection to further decrease the pain of local anaesthesia injection (Figure 4). These were originally developed for the cosmetic injection of hyaluronic fillers. The blunt tipped cannulas slide in the fat without piercing and irritating the nerves. These filler cannulas permit much more pain-free rapid injection of large areas of subcutaneous tissue. This is especially helpful when one is performing forearm tendon transfers that require a large area of injection.

### *Improvement in using for carpal tunnel*

The main improvement for carpal tunnel is the complete elimination of unnecessary tourniquet pain and

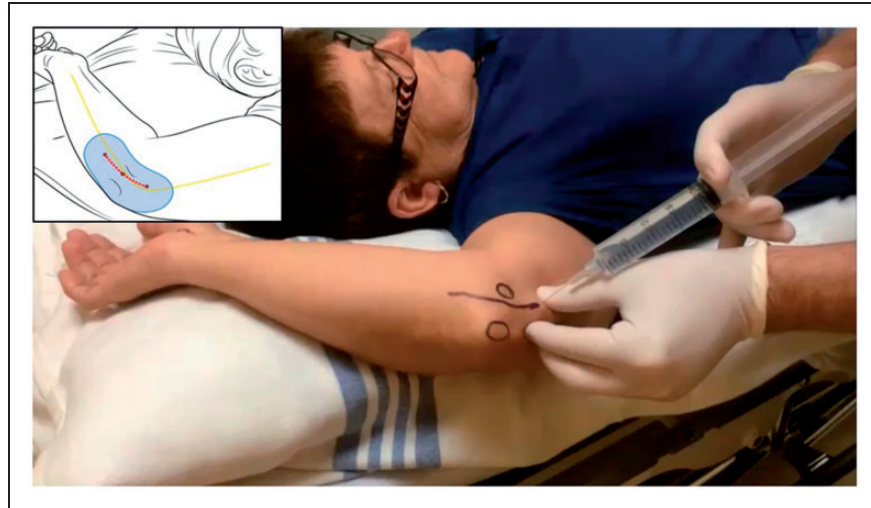

**Figure 4.** Blunt tipped cannula for rapid painless local anaesthesia injection over large areas. A 25-gauge needle is inserted in numbed skin to make an insertion hole. A 27-gauge 1.5 or 2 inch blunt tipped cannula is inserted into the hole. It glides painlessly in the fat for rapid painless injection of tumescent local anaesthesia. (Illustration reproduced with permission from McKee and Lalonde, 2017).

sedation. Patients all 'tolerate' the tourniquet, but they all hate it. It is just no longer necessary. In Canada, these procedures are now mostly done with no sedation and no tourniquet in the clinic or office outside the main operating room and with field sterility (Leblanc et al., 2007, 2011). WALANT minor procedures are increasingly popular in most countries, from China through England to the United States and Brazil, as patients come to understand the more affordable simplicity, comfort, and conveniences of the procedure (Bismil et al., 2012; Hoffman, 2017; Rhee et al., 2017; Sardenberg et al., in press; Tang et al., 2017a).

The main minor hurdle for most surgeons is using epinephrine instead of the tourniquet. When surgeons finally try it, they are usually very satisfied that bleeding is minimal if they give the epinephrine time to work. I inject two or three patients on stretchers outside the procedure room before doing the first one to allow the optimal 26 minutes for epinephrine to provide maximal vasoconstriction (McKee et al. 2013; 2015). Senn retractors pull firmly on the wound edges to stop small bleeders that occasionally persist.

Minimal pain injection using the 'hole in one' technique limits the pain to a single poke of a 27-gauge needle in the wrist (Lalonde, 2010). Ten millilitres in



**Figure 5.** Cubital tunnel release with the hand above the head. Without the tourniquet and anaesthesiology equipment at the head of the bed, this position brings the ulnar nerve to the anterior position for easier accessibility than when it is under the medial epicondyle in the traditional position. We start by injecting the local anaesthesia in this position to be sure it is comfortable for the patient. Insert: The illustrations of the incision and position.

the palm is sufficient for most patients, but will not prevent the occasional 'electric shock' feeling if the median nerve is not also blocked above the carpal tunnel.

#### *Improvement in using for trigger finger*

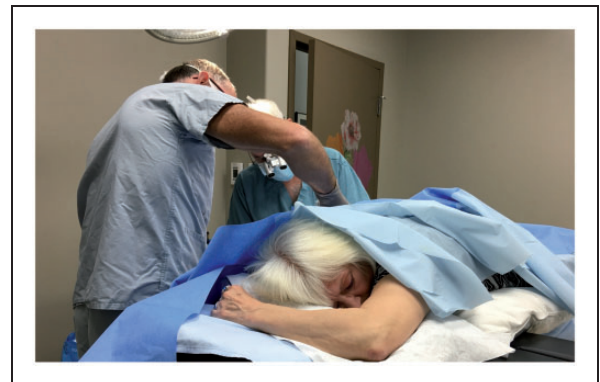Do not inject the local anaesthesia into the sheath when doing a trigger finger. It hurts more because the sheath is a confined space that 'explodes' with sheath injection (Zhu et al., 2017). In addition, the epinephrine runs to the fingertip with intra-sheath injection and creates an unnecessary white finger. Simply slowly inject 4 ml in the subcutaneous fat in the centre of the incision without moving the needle and give it 30 minutes or more to work. This will numb the sheath.

#### *Improvement in using for De Quervain release*

As for the trigger finger, do not inject the local anaesthetic into the sheath because it creates a lot of unnecessary pain. Simply slowly inject 10 ml in the subcutaneous fat in the centre of the incision without moving the needle and give it 30 minutes or more to work. This will numb the sheath.

#### *Use for cubital tunnel release*

Eliminating the tourniquet and anaesthesiology equipment at the head of the table now permits



**Figure 6.** Prone position for cubital tunnel release. For patients who comfortably sleep prone with their arm to be operated by their side, this position provides easy access to the ulnar nerve with the elbow extended and the cubital tunnel in a loose position.

new positions of the arm over the head (Figure 5) or the arm at the side with the patient prone if they are comfortable lying this way (Figure 6). Both positions provide better and easier exposure of the ulnar nerve at the elbow than the traditional tourniquet supine approach with the arm abducted at 90°.

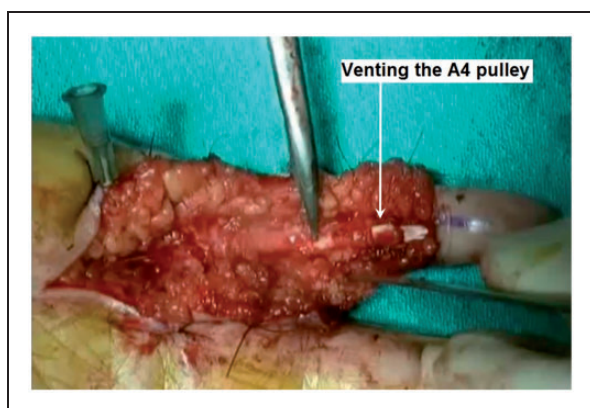
#### *Use for lacertus release*

I have abandoned the traditional pronator operation with the long incision above and below the elbow in favour of the Hagert approach (Hagert, 2013; Hagert and Lalonde, 2016). This is performed with a 3-cm

incision in the elbow crease to divide the fibrous band of the lacertus fibrosis that constricts the median nerve in the proximal forearm. It is similar in concept to dividing the fibrous bands of the transverse carpal ligament that constrict the median nerve in the proximal palm. The great advantage of doing this procedure awake is that the surgeon and the patient both get to see the return of power of flexor pollicis longus and index flexor digitorum profundus before the skin is closed.

### *Use in flexor tendon repair*

Of all the procedures performed with wide awake hand surgery, the most improved is the flexor tendon repair. The five main advantages of wide awake flexor tendon repair are as follows. (1) Decreased rupture rate of 7% because the active full fist flexion extension test by the patient with intraoperative active movement permit observation and repair of gap from sutures not tied tightly enough (Higgins et al., 2010). (2) Decreased tenolysis because of judicious venting of pulleys (including the entire A4 and up to half of the A2 pulley) until the flexion extension test reveals full free gliding of the repair (Figure 7) (Tang, 2007, 2014; Tang et al., 2016). (3) Intraoperative patient education about the importance of adhering to the rules of postoperative therapy (Lalonde et al., 2016; Lalonde and Higgins, 2016; Lalonde and McGrouther, 2016). (4) Seeing the flexion extension test without a gap gives the surgeon conviction to perform up to half a fist of true active movement postoperatively (Higgins and Lalonde, 2016). (5) The surgeon can decide on whether or not to preserve a superficialis repair



**Figure 7.** Pulleys are gradually vented as required until full fist flexion and extension (flexion–extension test) during wide awake flexor tendon repair.

based on what he sees with the active full fist flexion extension test (Tang et al., 2016).

Flexor tendon repair in the thumb and trigger thumb release are easier if the patient is prone, as suggested by Dr Thomas Aparid from France. The prone position is simple in wide awake patients.

Postoperative flexor tendon repair rehabilitation is also changing and improving because of watching repaired flexor tendons move with active full fist flexion–extension testing during surgery. The observation of tendon buckling and jerking when we ask patients to full fist place and hold during wide awake surgery has led us to abandon this technique in favour of up to half a fist of true active movement as espoused by Jin Bo Tang (Tang et al., 2016; Tang, 2017b).

### *Use in tendon transfer*

Our initial experience began with simple extensor indicis to extensor pollicis longus (Lalonde, 2014). We have now done several complex forearm transfers. It is particularly helpful to do these awake in situations where the excursion of the transfer motors is unknown because of previous trauma.

### *Use in finger and hand fractures*

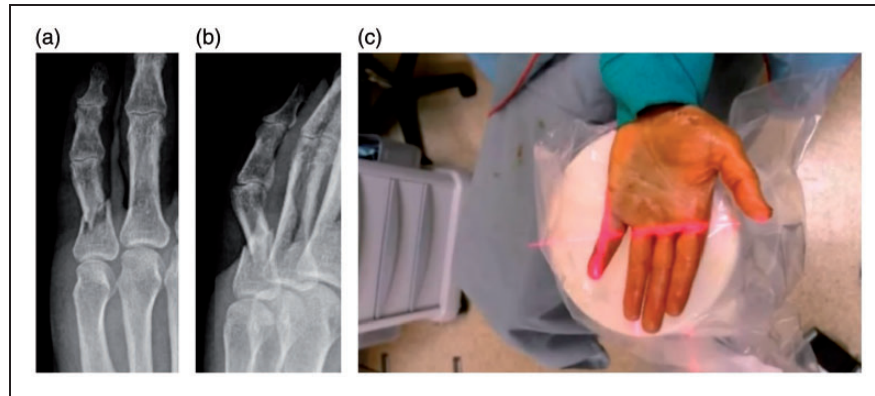
All hand and finger fractures are easily plated or Kirchner (K)-wired with the wide awake approach. One of the most useful improvements is assessing the stability of K-wired finger fractures with full fist flexion and extension testing during surgery. If there is enough stability, we go onto pain-guided early protected movement with K-wired finger fractures (Jones et al., 2012) (Figure 8).

### *Use in distal radius fracture plating*

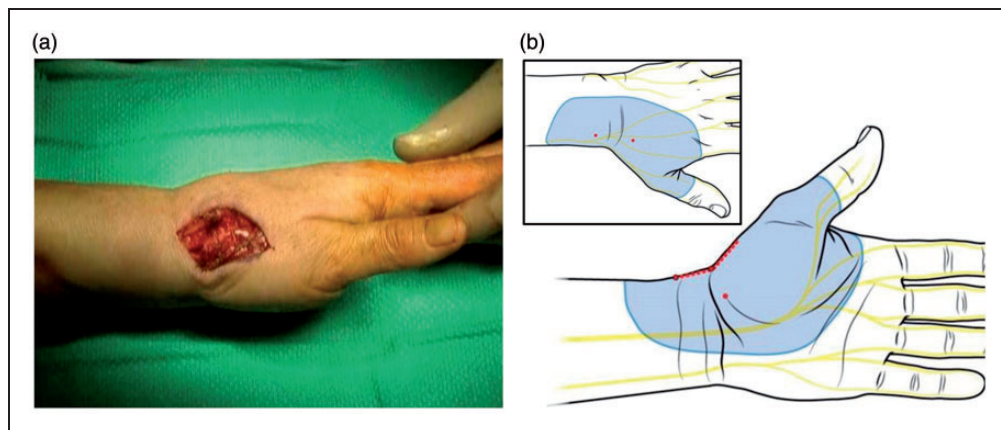
All hand fractures and wrist procedures can be performed easily with this approach (Lalonde, 2016b). What is new in fracture treatment is that Dr Gilles Candelier of France has performed over 30 cases of WALANT tumescent local anaesthesia to plate distal radius fractures.

### *Use in trapeziectomy*

The new development in trapeziectomy for basal joint arthritis is the ability to decide whether ligament reconstruction should be performed or not based on observing active thumb movement after trapezium excision. If the metacarpal base is grinding on the scaphoid, we add ligament reconstruction. If there is no grinding, we stop at trapeziectomy (Figure 9).



**Figure 8.** Hand fractures shown in (a) and (b). After K-wiring of the fracture, the fingers can move under fluoroscopy (c) in the patient to see whether K-wire fixation is stable enough to permit early protected movement.



**Figure 9.** Wide awake trapeziectomy for thumb basal joint arthritis. Surgical incision is shown in the left and the area of anaesthesia shown in the right. After resecting the trapezium, we get the patient to take the thumb through a full range of movement to see if the metacarpal is grinding on the scaphoid with movement. If there is no grinding, we stop at trapeziectomy. If there is grinding we do an abductor pollicis longus (APL) ligament reconstruction. Flexor carpi radialis (FCR) ligament reconstruction can be done with additional tumescent injection of local over the FCR.

### Rapid world-wide adoption of the technique

Many have contributed to the very rapid expansion of WALANT surgery. The simplicity, safety, convenience, and affordable nature of the technique are very appealing to both surgeons and patients. Electronic media such as ASSH listserv, Vumedi videos, PubMed, and Google links to scientific publications are rapidly available to most hand surgeons of the world. The publication of the first book of *Wide awake hand surgery* in 2016 (Lalonde, 2016b) with over 150 videos helped greatly. The Chinese version of the book edited by Jin Bo Tang came out in July 2017.

Perhaps the most important thing has been the willingness of world opinion leaders in hand surgery to use and promote the technique, as well as to invite its presentations at their hand surgery meetings. To name only a few would include Jin Bo Tang (China), Teddy Prasetyono (Indonesia), Koji Moriya (Japan), Fu Chan Wei (Taiwan), Wan Siu Ho, PC Ho (Hong Kong), Shalimar Abdullah (Malaysia), Steven Frederiksen, Greg Bain, Jeff Ecker (Australia), Keith Denkler, Peter Amadio, Mark Baratz, Peter Stern (USA), Raja Sabapathy, Abkar Khan (India), Nebojsa Jovanovic (UAE), Carlos Fernandez, Sergio Gama, Pedro Pirez (Brazil), Carlos Martinez (Argentina), Michael Sauerbier, Gunter Germann (Germany), Elisabet Hagert (Sweden), Franco Bassetto, Roberto Adani



(Italy), Paco Pinal, Lydia Jiménez (Spain), and Duncan McGrouther (UK and Singapore).

## What is the future of wide awake hand surgery?

I believe that most small hand surgery procedures will be performed this way for most patients by the year 2050. For flexor tendon operations, such as repair, transfer, reconstruction, and tenolysis, it will become the gold standard to avoid rupture and the need for revision surgery. I speculate that most hand, wrist, and distal radius fracture repairs will also be managed this way so surgeons can see active movement at the end of the case, and provide intraoperative patient education to decrease postoperative complications. For patients with major medical comorbidities who have major sedation risk, it will become the anaesthesia of choice for safety reasons.

I suspect that evidence-based sterility (Leblanc et al., 2011) will eventually replace the customary 'more must be better' custom-based sterility practices for non-implant hand surgery. This will take a lot of the hand surgery currently performed in the main operating room out into clinics and offices. This will greatly decrease costs and garbage production, and increase surgeon and patient convenience. I have a young foot and ankle orthopaedic surgery colleague in Saint John named Josh Mayich. He is widely practicing, publishing, and presenting on the wide awake approach to foot and ankle surgery. This will only grow in popularity for the same reasons as wide awake hand surgery.

The wide awake approach is one of the few innovations that requires 'much less' instead of 'much more' in terms of resources and time. In this instance, the adage of 'less is more' is definitely accurate.

**Declaration of conflicting interests** The author(s) declared the following potential conflicts of interest with respect to the research, authorship, and/or publication of this article: Dr Lalonde has edited a book on *Wide awake hand surgery*, but receives no money in royalties. All royalties from the book go to the lean and green effort of the American Association for Hand Surgery, which is dedicated to reducing unnecessary garbage and cost in hand surgery.

**Funding** The authors received no financial support for the research, authorship, and/or publication of this article.

## References

Bismil MS, Bismil QM, Harding D et al. Transition to total one-stop wide-awake hand surgery service audit: a retrospective review. *JRSM Short Rep.* 2012, 3: 23.  
Bunnell S. *Surgery of the Hand* J. B. Lippincott Company, 1st edition, 1944.

Burk RW 3rd, Guzman-Stein G, Vasconez LO. Lidocaine and epinephrine levels in tumescent technique liposuction. *Plast Reconstr Surg.* 1996, 97: 1379-84.  
Chowdhry S, Seidenstricker L, Cooney DS, Hazani R, Wilhelmi BJ. Do not use epinephrine in digital blocks: myth or truth? Part II. A retrospective review of 1111 cases. *Plast Reconstr Surg.* 2010, 126: 2031-4.  
Denkler K. A comprehensive review of epinephrine in the finger: to do or not to do. *Plast Reconstr Surg.* 2001, 108: 114-24.  
Farhangkhoei H, Lalonde J, Lalonde DH. Teaching medical students and residents how to inject local anesthesia almost painlessly. *Can J Plast Surg.* 2012, 20: 169-72.  
Frank SG, Lalonde DH. How acidic is the lidocaine we are injecting, and how much bicarbonate should we add? *Can J Plast Surg.* 2012, 20: 71-3.  
Food and Drug Administration. Warning-procaine solution. *JAMA.* 1948, 138: 599.  
Fitzcharles-Bowe C, Denkler K, Lalonde D. Finger injection with high-dose (1:1,000) epinephrine: does it cause finger necrosis and should it be treated? *Hand (NY).* 2007, 2: 5-11.  
Hagert E. Clinical diagnosis and wide-awake surgical treatment of proximal median nerve entrapment at the elbow: a prospective study. *Hand (NY).* 2013, 8: 41-6.  
Hagert E, Lalonde DH. Lacertus syndrome: median nerve release at the elbow. In: Lalonde DH (Ed.) *Wide awake hand surgery*. New York, Thieme, 2016: 141-3.  
Higgins A, Lalonde DH. Flexor tendon repair postoperative rehabilitation: The Saint John protocol. *Plast Reconstr Surg Glob Open.* 2016, 4: e1134.  
Higgins A, Lalonde DH, Bell M, Mckee D, Lalonde JF. Avoiding flexor tendon repair rupture with intraoperative total active movement examination. *Plast Reconstr Surg.* 2010, 126: 941-5.  
Hoffman J. Going under the knife with eyes and ears wide open. *New York Times.* 25 March 2017.  
Hustedt JW, Chung A, Bohl DD et al. Comparison of postoperative complications associated with anesthetic choice for surgery of the hand. *J Hand Surg Am.* 2017, 42: 1-8.  
Hutting K, van Rappard JR, Prins A et al. [Digital necrosis after local anaesthesia with epinephrine]. *Ned Tijdschr Geneesk.* 2015, 159: A9477.  
Jones NF, Jupiter JB, Lalonde DH. Common fractures and dislocations of the hand. *Plast Reconstr Surg.* 2012, 130: 722e.  
Klein JA. Tumescent technique for regional anesthesia permits lidocaine doses of 35 mg/kg for liposuction. *J Dermatol Surg Oncol.* 1990, 16: 248-63.  
Lalonde D. Wide-awake extensor indicis proprius to extensor pollicis longus tendon transfer. *J Hand Surg Am.* 2014, 39: 2297-9.  
Lalonde D, Bell M, Benoit P, Sparkes G, Denkler K, Chang P. A multi-center prospective study of 3,110 consecutive cases of elective epinephrine use in the fingers and hand: the Dalhousie Project clinical phase. *J Hand Surg Am.* 2005, 30: 1061-7.  
Lalonde D, Wong A. Local anesthetics: what's new in minimal pain injection and best evidence in pain control. *Plast Reconstr Surg.* 2014, 134: 40S-9S.  
Lalonde DH. "Hole-in-one" local anesthesia for wide awake carpal tunnel surgery. *Plast Reconstr Surg.* 2010, 126: 1642-4.  
Lalonde DH. What is wide awake hand surgery? In: Lalonde DH (Ed.) *Wide awake hand surgery*. New York, Thieme, 2016a: 17-22.  
Lalonde DH. *Wide awake hand surgery*. New York, Thieme, 2016b.  
Lalonde DH. Safe epinephrine in the finger means no tourniquet. In: Lalonde DH (Ed.) *Wide awake hand surgery*. New York, Thieme, 2016c: 37.  
Lalonde DH, Higgins A. Wide awake flexor tendon repair in the finger. *Plast Reconstr Surg Global Open.* 2016: e797.

- Lalonde DH, Jagodzinski N, Phillips A. How to inject local anaesthesia with minimal pain. In: Lalonde DH (Ed.) *Wide awake hand surgery*. New York, Thieme, 2016a: 37–48.
- Lalonde DH, McGrouther D. Talking with patients during surgery saves time. In: Lalonde DH (Ed.) *Wide awake hand surgery*. New York, Thieme, 2016: 59–64.
- Lalonde DH, Phillips A, McGrouther D, Tumescent local anaesthesia. In: Lalonde DH (Ed.) *Wide awake hand surgery*. New York, Thieme, 2016b: 29–36.
- Lalonde DH, Wong A. Dosage of local anesthesia in wide awake hand surgery. *J Hand Surg Am*. 2013, 38: 2025–8.
- Leblanc MR, Lalonde J, Lalonde DH. A detailed cost and efficiency analysis of performing carpal tunnel surgery in the main operating room versus the ambulatory setting in Canada. *Hand (NY)*. 2007, 2: 173–8.
- Leblanc MR, Lalonde DH, Thoma A et al. Is main operating room sterility really necessary in carpal tunnel surgery? A multicenter prospective study of minor procedure room field sterility surgery. *Hand (NY)*. 2011, 6: 60–3.
- Mann T, Hammert WC. Epinephrine and hand surgery. *J Hand Surg Am*. 2012, 37: 1254–6.
- McKee DE, Lalonde DH, Thoma A, Glennie DL, Hayward JE. Optimal time delay between epinephrine injection and incision to minimize bleeding. *Plast Reconstr Surg*. 2013, 131: 811–4.
- McKee DE, Lalonde DH, Thoma A, Dickson L. Achieving the optimal epinephrine effect in wide awake hand surgery using local anesthesia without a tourniquet. *Hand*. 2015: 613–5.
- McKee D, Lalonde D. Minimal pain local anesthetic injection with blunt tipped cannula for wide awake upper blepharoplasty. *Plast Reconstr Surg Glob Open*. 2017: e1310.
- Muck AE, Bebarta VS, Borys DJ, Morgan DL. Six years of epinephrine digital injections: absence of significant local or systemic effects. *Ann Emerg Med*. 2010, 56: 270–4.
- Nodwell T, Lalonde D. How long does it take phentolamine to reverse adrenaline-induced vasoconstriction in the finger and hand? A prospective randomized blinded study: the Dalhousie project experimental phase. *Can J Plast Surg*. 2003, 11: 187–90.
- Ravindran V, Rajendran S. Digital gangrene in a patient with primary Raynaud's phenomenon. *J R Coll Physicians Edinb*. 2012, 42: 24–6.
- Rhee PC, Fischer MM, Rhee LS, McMillan H, Johnson AE. Cost savings and patient experiences of a clinic-based, wide-awake hand surgery program at a military medical center: a critical analysis of the first 100 Procedures. *J Hand Surg Am*. 2017, 42: e139–47.
- Ruiter T, Harter T, Miladore N et al. Finger amputation after injection with lidocaine and epinephrine. *Interesting Case*, 3 November 2014, 3; 14: ic43. [www.ePlasty.com](http://www.ePlasty.com).
- Sama CB. Post-traumatic digital gangrene associated with epinephrine use in primary Raynaud's phenomenon: lesson for the future. *Ethiop J Health Sci*. 2016, 26: 401–4.
- Sardenberg T, Ribak S, Colencia R et al. 488 cirurgias da mão com anestesia local com epinefrina, sem torniquete, sem sedação e sem anestesista. Portuguese in *Rev Bras Ortop*. In press. .
- Strazar AR, Leynes PG, Lalonde DH. Minimizing the pain of local anesthesia injection. *Plast Reconstr Surg*. 2013, 132: 675–84.
- Tang JB. Indications, methods, postoperative motion and outcome evaluation of primary flexor tendon repairs in Zone 2. *J Hand Surg Eur*. 2007, 32: 118–29.
- Tang JB. Release of the A4 pulley to facilitate zone II flexor tendon repair. *J Hand Surg Am*. 2014, 39: 2300–7.
- Tang JB. *Wide awake hand surgery*. Shanghai Science and Technology Press, Shanghai, 2017.
- Tang JB, Xing SG, Wong J, Lalonde DH. Flexor tendon repair of the finger. In: Lalonde DH (Ed.) *Wide awake hand surgery*. New York, Thieme, 2016: 187–226.
- Tang JB, Gong KT, Zhu L, Pan ZJ, Xing SG. Performing hand surgery under local anesthesia without a tourniquet in China. *Hand Clin*. 2017a, 33: 415–24.
- Tang JB, Zhou X, Pan ZJ et al. Strong digital flexor tendon repair, extension-flexion test, and early active flexion: experience in 300 tendons. *Hand Clin*. 2017b, 33: 455–63.
- Thomson CJ, Lalonde DH, Denkler KA, Feicht AJ. A critical look at the evidence for and against elective epinephrine use in the finger. *Plast Reconstr Surg*. 2007, 119: 260–6.
- Zhang JX, Gray J, Lalonde DH, Carr N. Digital necrosis after lidocaine and epinephrine injection in the flexor sheath without phentolamine rescue. *J Hand Surg Am*. 2017, 42: 119–23.
- Zhu AF, Hood BR, Morris MS, Ozer K. Delayed-onset digital ischemia after local anesthetic with epinephrine injection requiring phentolamine reversal. *J Hand Surg Am*. 2017, 42: 479.e1–4.